

See discussions, stats, and author profiles for this publication at: <https://www.researchgate.net/publication/309543226>

Evidence-based guidelines on the therapeutic use of transcranial direct current stimulation (tDCS)

Article in *Clinical neurophysiology: official journal of the International Federation of Clinical Neurophysiology* · October 2016

DOI: 10.1016/j.clinph.2016.10.087

CITATIONS

502

READS

3,988

23 authors, including:



Andrea Antal

Universitätsmedizin Göttingen

327 PUBLICATIONS 19,715 CITATIONS

[SEE PROFILE](#)



Samar S. Ayache

Hôpital Henri Mondor (Hôpitaux Universitaires Henri Mondor)

176 PUBLICATIONS 3,591 CITATIONS

[SEE PROFILE](#)



David Benninger

Lausanne University Hospital

67 PUBLICATIONS 3,386 CITATIONS

[SEE PROFILE](#)



Jerome Brunelin

Lyon Neuroscience Research Center

184 PUBLICATIONS 4,231 CITATIONS

[SEE PROFILE](#)

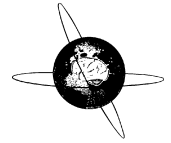
Some of the authors of this publication are also working on these related projects:



tDCS in Autistic Disorder [View project](#)



Adaptive deep brain stimulation [View project](#)



Guidelines

Evidence-based guidelines on the therapeutic use of transcranial direct current stimulation (tDCS)



Jean-Pascal Lefaucheur^{a,b,*}, Andrea Antal^c, Samar S. Ayache^{a,b}, David H. Benninger^d, Jérôme Brunelin^e, Filippo Cogiamanian^{f,g}, Maria Cotelli^h, Dirk De Ridder^{i,j}, Roberta Ferrucci^{f,g}, Berthold Langguth^k, Paola Marangolo^{l,m}, Veit Mylius^{n,o}, Michael A. Nitsche^{p,q}, Frank Padberg^r, Ulrich Palm^r, Emmanuel Poulet^{e,s}, Alberto Priori^{f,g,t}, Simone Rossi^u, Martin Scheckmann^k, Sven Vanneste^{v,w}, Ulf Ziemann^x, Luis Garcia-Larrea^{y,1}, Walter Paulus^{c,1}

^a Department of Physiology, Henri Mondor Hospital, Assistance Publique – Hôpitaux de Paris, Créteil, France

^b EA 4391, Nerve Excitability and Therapeutic Team (ENT), Faculty of Medicine, Paris Est Créteil University, Créteil, France

^c Department of Clinical Neurophysiology, University Medical Center, Georg-August University, Göttingen, Germany

^d Department of Clinical Neurosciences, Section of Neurology, Centre Hospitalier Universitaire Vaudois, Lausanne, Switzerland

^e PsyR2 Team, U 1028, INSERM and UMR 5292, CNRS, Center for Neuroscience Research of Lyon (CRNL), CH Le Vinatier, Lyon-1 University, Bron, France

^f Clinica Neurologica III, Dipartimento di Scienze della Salute, Azienda Ospedaliera Santi Paolo e Carlo, Università degli Studi di Milano, Milano, Italy

^g IRCCS Fondazione Ospedale Maggiore Policlinico, Milano, Italy

^h Neuropsychology Unit, IRCCS Fondazione Istituto Centro San Giovanni di Dio Fatebenefratelli, Brescia, Italy

ⁱ Brai²n, Tinnitus Research Initiative Clinic of Antwerp, Sint Augustinus Hospital, Wilrijk, Belgium

^j Department of Surgical Sciences, Section of Neurosurgery, Dunedin School of Medicine, University of Otago, Dunedin, New Zealand

^k Department of Psychiatry and Psychotherapy, University of Regensburg, Regensburg, Germany

^l Dipartimento di Studi Umanistici, University Federico II, Naples, Italy

^m IRCCS Fondazione Santa Lucia, Rome, Italy

ⁿ Department of Neurology, Section Pain and Neuromodulation, University of Marburg, Marburg, Germany

^o Department of Neurology, Center for Neurorehabilitation, Valens, Switzerland

^p Department of Psychology and Neurosciences, Leibniz Research Centre for Working Environment and Human Factors, Dortmund, Germany

^q Department of Neurology, University Medical Hospital Bergmannsheil, Bochum, Germany

^r Department of Psychiatry and Psychotherapy, Ludwig Maximilian University, Munich, Germany

^s Department of Emergency Psychiatry, Edouard Herriot Hospital, Hospices Civils de Lyon, Lyon, France

^t Dipartimento di Fisiopatologia Medico-Chirurgica e dei Trapianti, Università degli Studi di Milano, Milano, Italy

^u Unit of Neurology and Clinical Neurophysiology, Brain Investigation & Neuromodulation Lab, Department of Neuroscience, and Human Physiology Section, Siena University, Siena, Italy

^v Department of Translational Neuroscience, Faculty of Medicine, University of Antwerp, Edegem, Belgium

^w Laboratory for Auditory and Integrative Neuroscience, School of Behavioral and Brain Sciences, The University of Texas, Dallas, TX, USA

^x Department of Neurology & Stroke, and Hertie Institute for Clinical Brain Research, Eberhard Karls University, Tübingen, Germany

^y NeuroPain Team, U 1028, INSERM, Center for Neuroscience Research of Lyon (CRNL), Lyon-1 University, Bron, France

ARTICLE INFO

Article history:

Accepted 20 October 2016

Available online 29 October 2016

HIGHLIGHTS

- A group of European experts reviewed current evidence for therapeutic efficacy of tDCS.
- Level B evidence (probable efficacy) was found for fibromyalgia, depression and craving.
- The therapeutic relevance of tDCS needs to be further explored in these and other indications.

Abbreviations: AD, Alzheimer's disease; ARAT, action research arm test; BDI, Beck Depression Inventory; BI, Barthel Index; DC, direct current; DLPFC, dorsolateral prefrontal cortex; EEG, electroencephalography; ERP, event-related potentials; FMA, Fugl-Meyer assessment; fMRI, functional magnetic resonance imaging; GABA, gamma-aminobutyric acid; HDRS, Hamilton Depression Rating Scale; JTT, Jebsen–Taylor hand function test; M1, primary motor cortex; MADRS, Montgomery–Asberg depression rating scale; MCS, minimally conscious state; MEP, motor evoked potential; NMDA, N-methyl D-aspartate; OMCASS, Orgogozo MCA scale; PANSS, positive and negative symptoms scale; PD, Parkinson's disease; PES, peripheral electrical stimulation; RCT, randomized controlled trial; rTMS, repetitive transcranial magnetic stimulation; SANS, Scale for the Assessment of Negative Symptoms; tACS, transcranial alternating current stimulation; tDCS, transcranial direct current stimulation; TMS, transcranial magnetic stimulation; tRNS, transcranial random noise stimulation; tsDCS, transcutaneous spinal direct current stimulation; UPDRS, unified Parkinson's disease rating scale; V1, primary visual cortex; VAS, visual analogue scale; VRT, virtual reality training; VS, vegetative state.

* Corresponding author at: Service Physiologie, Explorations Fonctionnelles, Hôpital Henri Mondor, 51 avenue de Lattre de Tassigny, 94010 Créteil cedex, France. Fax: +33 1 4981 4660.

E-mail address: jean-pascal.lefaucheur@hmn.aphp.fr (J.-P. Lefaucheur).

¹ Equal contribution.

<http://dx.doi.org/10.1016/j.clinph.2016.10.087>

1388-2457/© 2016 International Federation of Clinical Neurophysiology. Published by Elsevier Ireland Ltd. All rights reserved.

A B S T R A C T

Keywords:

Cortex
 Indication
 Neurological disease
 Neuromodulation
 Noninvasive brain stimulation
 Psychiatric disease
 tDCS
 Treatment

A group of European experts was commissioned by the European Chapter of the International Federation of Clinical Neurophysiology to gather knowledge about the state of the art of the therapeutic use of transcranial direct current stimulation (tDCS) from studies published up until September 2016, regarding pain, Parkinson's disease, other movement disorders, motor stroke, poststroke aphasia, multiple sclerosis, epilepsy, consciousness disorders, Alzheimer's disease, tinnitus, depression, schizophrenia, and craving/addiction. The evidence-based analysis included only studies based on repeated tDCS sessions with sham tDCS control procedure; 25 patients or more having received active treatment was required for Class I, while a lower number of 10–24 patients was accepted for Class II studies. Current evidence does not allow making any recommendation of Level A (definite efficacy) for any indication. Level B recommendation (probable efficacy) is proposed for: (i) anodal tDCS of the left primary motor cortex (M1) (with right orbitofrontal cathode) in fibromyalgia; (ii) anodal tDCS of the left dorsolateral prefrontal cortex (DLPFC) (with right orbitofrontal cathode) in major depressive episode without drug resistance; (iii) anodal tDCS of the right DLPFC (with left DLPFC cathode) in addiction/craving. Level C recommendation (possible efficacy) is proposed for anodal tDCS of the left M1 (or contralateral to pain side, with right orbitofrontal cathode) in chronic lower limb neuropathic pain secondary to spinal cord lesion. Conversely, Level B recommendation (probable inefficacy) is conferred on the *absence* of clinical effects of: (i) anodal tDCS of the left temporal cortex (with right orbitofrontal cathode) in tinnitus; (ii) anodal tDCS of the left DLPFC (with right orbitofrontal cathode) in drug-resistant major depressive episode. It remains to be clarified whether the probable or possible therapeutic effects of tDCS are clinically meaningful and how to optimally perform tDCS in a therapeutic setting. In addition, the easy management and low cost of tDCS devices allow at home use by the patient, but this might raise ethical and legal concerns with regard to potential misuse or overuse. We must be careful to avoid inappropriate applications of this technique by ensuring rigorous training of the professionals and education of the patients.

© 2016 International Federation of Clinical Neurophysiology. Published by Elsevier Ireland Ltd. All rights reserved.

Contents

1. Principles and mechanisms of action of transcranial direct current stimulation	58
2. Clinical applications of tDCS: literature data analysis	59
3. Pain	60
4. Parkinson's disease	63
4.1. tDCS effects on motor symptoms	63
4.2. tDCS effects on nonmotor symptoms	63
4.3. Conclusion	64
5. Other movement disorders	64
6. Motor stroke	65
7. Aphasia	68
8. Multiple sclerosis	69
9. Epilepsy	71
10. Disorders of consciousness	72
11. Alzheimer's disease	72
12. Tinnitus	72
13. Depression	74
13.1. Antidepressant effects	75
13.2. Cognitive effects	76
14. Schizophrenia	76
15. Substance abuse, addiction and craving	78
16. Other psychiatric disorders	79
17. At-home do-it-yourself DCS and neural enhancement	80
18. Perspectives of targets other than cortical (cerebellum and spinal cord)	80
18.1. Cerebellar tDCS	80
18.2. Transcutaneous spinal direct current stimulation	81
19. Perspectives of treatment by transcranial electrical stimulation methods other than tDCS (tACS, tRNS)	81
20. Summary of recommendations	82
Conflict of interest	83
References	83

1. Principles and mechanisms of action of transcranial direct current stimulation

Alterations of neuroplasticity and cortical excitability are important pathophysiological factors in many neuropsychiatric diseases. Thus, to modify cortical activities by using non-invasive brain stimulation (NIBS) might be a valuable therapeutic approach. One of these NIBS approaches is transcranial direct current stimulation (tDCS). Fifty years ago, it has been demonstrated in anesthetized rats that neural activity and cortical excitability could be modified by the application of direct current on the sensorimotor cortex, these effects depending on stimulation polarity and persisting for hours after the end of stimulation (Bindman et al., 1964). A few years later, it was established that a current flow sufficiently large to achieve physiological and functional effects could also be induced into the brain via transcranial application of such direct currents in both healthy subjects and patients suffering from psychiatric diseases (Rush and Driscoll, 1968; Dymond et al., 1975; Lolas, 1977). However, mainly due to the lack of relevant tools to assess its heterogeneous effects, this technique was nearly forgotten in the following years. About 15 years ago, tDCS was re-discovered as a tool to modulate human brain activity and its physiological effects started to be systematically explored (Priori et al., 1998; Nitsche and Paulus, 2000).

The primary effect of tDCS on neurons is a subthreshold shift of resting membrane potentials towards depolarization or hyperpolarization, depending on current flow direction relative to axonal orientation (Bindman et al., 1962, 1964; Purpura and McMurtry, 1965; Gorman, 1966). Delivered to the motor cortex of healthy subjects, anodal tDCS increases the excitability of the underlying cortex, as revealed by an increase in the amplitude of motor evoked potential (MEP) to transcranial magnetic stimulation (TMS), whereas cathodal tDCS decreases it (Nitsche and Paulus, 2000). Stimulation of short duration (several seconds) is sufficient to induce these excitability changes, which however does not relevantly outlast the stimulation period (Priori et al., 1998; Nitsche and Paulus, 2000). A longer stimulation duration (several minutes) induces excitability changes that can last for one hour or more (Nitsche and Paulus, 2001; Nitsche et al., 2003b; Priori, 2003). As shown by a navigated TMS study, M1 excitability changes become steadily significant after the end of tDCS application rather than during stimulation (Santarnecchi et al., 2014). In these studies cited above, M1 was primarily targeted, but similar tDCS effects were obtained for the stimulation of visual (Antal et al., 2004) and somatosensory (Matsunaga et al., 2004) cortices.

Overall, calcium-dependent synaptic plasticity of glutamatergic neurons is thought to play a key role in the outlasting neuroplastic mechanism of action of tDCS, since blockade of N-methyl D-aspartate (NMDA) receptors diminishes tDCS effects (Liebetanz et al., 2002; Nitsche et al., 2003a). In addition, tDCS can locally reduce gamma-aminobutyric acid (GABA) neurotransmission, regardless of stimulation polarity (Stagg et al., 2009) and this may also impact on glutamatergic plasticity due to the close relationship between the two neurotransmitters.

Beyond local effects, connective effects of tDCS have also been described. Neuronal networks respond to DC fields even more sensitively than single neurons (Francis et al., 2003) and tDCS may interfere with functional connectivity, synchronization, and oscillatory activities in various cortical and subcortical networks. This has been shown for tDCS delivered to M1 (Polanía et al., 2011a,b, 2012), the prefrontal cortex (Keeser et al., 2011a), or during slow-wave sleep (Marshall et al., 2004).

In addition, since tDCS modulates resting membrane potential at the synaptic level but more generally along the whole axons, this may result in non-synaptic effects, which might also contribute to

the long-lasting after-effects of tDCS (Ardolino et al., 2005). These non-synaptic mechanisms of tDCS might be based on changes of conformation and function of various axonal molecules, involved in transmembrane ion conductance, membrane structure, cytoskeleton, or axonal transport, when exposed to a DC field (Jefferys, 1995).

Another important consideration in understanding tDCS effects is that almost all tissues and cells are sensitive to electric fields and, therefore, tDCS might also elicit changes in non-neuronal tissues in the brain, including endothelial cells, lymphocytes, or glial cells (Ruohonen and Karhu, 2012). These non-neuronal effects, which have not been systematically explored to date, could also be involved in the therapeutic action of tDCS. In patients with cerebral diseases, besides neuronal damage, other important pathological processes may exist in the axonal microenvironment, such as inflammation. Beyond neuroinflammatory diseases, such as multiple sclerosis, inflammation in the central nervous system has been implicated in several neuropsychiatric conditions, such as in the progression of neurodegeneration in Alzheimer's disease (AD) (Heneka et al., 2015). Hence, through its possible influence on the inflammatory response, tDCS might theoretically impact on the course of the disease. Also relevant in AD, one should note that the conformation of beta-amyloid and other pathological proteins can be changed when exposed to appropriate electric fields (Toschi et al., 2009), possibly modifying their susceptibility to degradation. In addition, DC fields can enhance axonal regeneration and neurite outgrowth (Fehlings and Tator, 1992; Wood and Willits, 2006; Pelletier et al., 2014) and therefore hypothetically improve functional recovery. Finally, tDCS could also be useful to limit the vicious circle of autodestructive events due to the increased Ca^{2+} influx resulting from excessive membrane depolarization or intra-axonal Na^{+} overload in the context of ischemia or energetic resource failure (Lefaucheur, 2009). In other words, tDCS might be able to influence several pathological processes and pathogenetic cascades in the central nervous system, well beyond the sole change of neuronal excitability.

The classical influence of tDCS polarity on cortical excitability (i.e. excitatory anodal tDCS versus inhibitory cathodal tDCS) primarily concerns motor cortex stimulation, but cannot be considered as a general rule, since numerous factors can turn facilitatory changes into inhibitory, and vice versa. The local cellular influence of DC fields into the brain is complex, depending on the distance and orientation of the axonal or somatodendritic axis with respect to the electric field (Purpura and McMurtry, 1965; Gluckman et al., 1996; Bikson et al., 2004). Axon terminals are thought to be two–three times more susceptible than somas to tDCS-induced polarization, but radial or tangential current flow did not determine the same changes in synaptic efficacy at axon terminal level, according to stimulating electrode polarity (Rahman et al., 2013). More precisely, axonal orientation could determine whether the DC field is excitatory or inhibitory, whereas dendritic orientation could affect the magnitude but not the direction of DC resulting effects (Kabakov et al., 2012). In addition, modeling studies showed that a focal cathodal stimulation applied on the surface of a gyrus only or preferentially activates 'horizontal' fibers with a directional component parallel to the electrode surface, whereas anodal stimulation rather excites fibres in the underlying cortex that are perpendicular to the electrode surface (Manola et al., 2005; Holsheimer et al., 2007a,b). Finally, even if DC fields induce coherent depolarizing or hyperpolarizing effects on neuronal populations with respect to fiber orientation and electrode polarity, the resulting physiological effect of the stimulation depends on whether the affected network is dominantly inhibitory or excitatory.

Baseline activity of the neural networks and afferent synaptic inputs exposed to DC fields also have a relevant influence,

according to the concept of metaplasticity (Abraham and Tate, 1997; Turrigiano and Nelson, 2004; Müller-Dahhaus and Ziemann, 2015), especially following the “Bienenstock–Cooper–Munro (BCM) model” (Bienenstock et al., 1982). This model assumes that synaptic depression is more likely occurring when postsynaptic activity is high, whereas synaptic potentiation is more likely occurring when postsynaptic activity is low. Thus, tDCS-induced plasticity differs whether tDCS is applied in a passive, relaxed subject or in a subject performing cognitive or motor task (Antal et al., 2007). Non-linear effects of tDCS have been described, depending on the relationship between tDCS parameters and the responsivity of various subtypes of neurotransmitter receptors and ion channels (Nitsche et al., 2012), which might entail a sudden lack of proportionality in stimulus–response relationships. In turn, neurotransmitters, especially dopamine, can exert a dosage-dependent, but non-linear effect on tDCS-induced plasticity (Monte-Silva et al., 2010b).

As underlying mechanism, it has been speculated that activation of neurons not only changes their membrane potential and firing rate but also reduces membrane resistance. This loss of resistance, or increase of conductance, may have a key importance for tDCS effects since electric fields can cause larger changes in transmembrane voltage in resting neurones with low membrane conductance than in active neurones with high membrane conductance (Paulus and Rothwell, 2016). Therefore, tDCS effects depend on complex spatial relationships between the stimulated active target field, its projection areas, the resting surrounding structures, the pathological alterations of transmitter systems, the medication taken by the patients (Brunoni et al., 2013a), and individual genetic polymorphisms (Plewnia et al., 2013).

One should also consider the major influence of stimulation parameters, such as intensity (Batsikadze et al., 2013) and session repetition timing (Monte-Silva et al., 2010a, 2013), which reflect some aspects of the non-linear relationship between tDCS settings and the biological effects produced. For example, increasing the strength and duration of stimulation may enhance its efficacy in given applications (e.g., Shekhwat et al., 2016), but this cannot be considered as a general rule. In fact, increasing tDCS intensity might also shift the direction of excitability changes, e.g., doubling intensity from 1 mA to 2 mA can switch inhibition produced by cathodal tDCS of M1 into excitation (Batsikadze et al., 2013). In addition, the induced electric field spreads and goes deeper into the brain as intensity increases, able to modify the nature of the recruited neural networks and therefore the resulting biological and clinical effects unexpectedly (Lefaucheur, 2012). Finally, it is crucial to take into account that even little variations of electrode size area, shape, or placement (montage) can strongly influence the “diffusion” of the current and the geometry of the induced DC fields into the brain (Miranda et al., 2009; Faria et al., 2011; Sadleir et al., 2012; Saturnino et al., 2015). Therefore, the clinical changes provided by tDCS may strongly vary according to many technical and neuroanatomical considerations and relationships (Priori, 2003; Datta et al., 2012; Parazzini et al., 2012; Brunoni et al., 2014c; Ho et al., 2014; Galletta et al., 2015; Senço et al., 2015). All these factors could explain the variable results provided by tDCS trials in pathological conditions. They should be taken into account for designing stimulation protocols and interpreting the effects of tDCS when applied in patients with neuropsychiatric diseases. Personalized therapeutic application of brain stimulation techniques might be developed in the future, especially in the light of new findings, which show profound interindividual variability of cortical excitability changes in response to cortical stimulation using tDCS (Lopez-Alonso et al., 2014, 2015; Wiethoff et al., 2014; Strube et al., 2015), as also shown for repetitive transcranial magnetic stimulation (rTMS) using either conventional protocols

(Sommer et al., 2002) or theta burst paradigms (Hamada et al., 2013).

2. Clinical applications of tDCS: literature data analysis

For each potential clinical indication of tDCS, a bibliographic search was carried out by several experts independently, using specific keywords that will be specified at the beginning of each section. Each expert then proceeded to a critical reading of all selected publications in order to classify them according to the following criteria, derived from those proposed by the European Federation of Neurological Societies (Brainin et al., 2004). First, the studies were classified (I–IV) according to decreasing value of evidence. A *Class I study* is an adequately data-supported, prospective, randomized, placebo-controlled clinical trial with masked outcome assessment in a representative population ($n \geq 25$ patients receiving active treatment). It should include (a) randomization concealment; (b) clearly defined primary outcomes; (c) clearly defined exclusion/inclusion criteria; (d) adequate accounting for dropouts and crossovers with numbers sufficiently low to have minimal potential for bias, and (e) relevant baseline characteristics substantially equivalent among treatment groups or appropriate statistical adjustment for differences. A *Class II study* is a randomized, placebo-controlled trial performed with a smaller sample size ($n \geq 10$, but < 25) or that lacks at least one of the above-listed criteria a–e. *Class III studies* include all other controlled trials, with less than 10 patients, or more than 10 patients, but having methodological limitations in the experimental design, control procedures, or objectives. *Class IV studies* are uncontrolled studies, case series, and case reports.

With the aim of establishing evidence of efficacy of a given tDCS protocol in any specific therapeutic indication, the experts then compared their respective classifications until they reached a consensus and applied these to the levels of evidence A to C, as follows, without considering Class IV studies. *Level A* (“definitely effective or ineffective”) requires at least two convincing Class I studies or one convincing Class I study and at least two convincing Class II studies. *Level B* (“probably effective or ineffective”) requires one Class I study and less than two Class II studies, or at least two convincing Class II studies, or one convincing Class II study and at least two convincing Class III studies. *Level C* (“possibly effective or ineffective”) requires one convincing Class II study and less than two Class III studies or at least two convincing Class III studies. No recommendation is made on one isolated Class I, II, or III study.

For this study, only placebo-controlled studies (using sham tDCS, according to either crossover or parallel-arm design), based on repeated daily sessions and including at least 10 patients receiving an “active” tDCS protocol, were retained for further analysis. The restriction to repeated session protocols was justified by the fact that the present work addresses the therapeutic effect of tDCS in chronic disorders, which requires tDCS sessions to be repeated to produce sustained effects.

Regarding grading of the “level of evidence”, we always considered recommendation for a specific indication (with the patients having the same disease with the same type of clinical features), using a specific stimulation protocol (with the same anode/cathode montage, irrespective of stimulation intensity (1–2 mA) or duration and number of sessions). In addition, single-center studies with the same indication and methodology coming from a given research group were only considered once (according to their best class).

For each indication, only clinical results reported in controlled studies, published before the end of the bibliographic search (September 1st, 2016), based on repeated tDCS sessions with sham tDCS control procedure, and including at least 10 patients receiving

active stimulation, were included in the evidence-based analysis. If at least two comparable studies with similar clinical indication and tDCS montage were published by independent research groups, data were summarized in a table.

These tables give the number of patients who actually received tDCS therapy, excluding dropouts. In trials with parallel arms, the respective number of patients in the active and control groups are indicated. In the “Results” column, the main results are usually summarized as a function of the significance of the effect of active tDCS versus control condition. Following this analysis, we propose an overview of the level of evidence that can be currently recommended for the therapeutic application of tDCS in a given clinical indication, according to specified parameters of stimulation, especially regarding electrode locations and montage.

In addition, to clarify certain points (e.g., possible mechanisms of action), to give a larger overview of the “therapeutic” potential of the technique, or to indicate the tracks of future developments, we were led to quote in the text and discuss various studies, despite their small sample size or their open-label or single-session design. These studies, however, were not taken into account in the evidence-based analysis.

3. Pain

The literature review included studies related to ongoing chronic pain, or acute postoperative pain, and therefore excludes publications on the use of tDCS to relieve pain experimentally induced in healthy subjects, reviewed elsewhere (Mylius et al., 2012). A PubMed search [keywords: tDCS AND (pain OR migraine)] identified 269 papers, including 62 original clinical studies covering 1426 patients. In all indications, we first screened literature data for original clinical trials, excluding any other papers, such as reviews, editorials, or experimental studies regarding animals or healthy subjects. From these 62 clinical trials, 17 included less than 10 patients. The types of pain syndrome were as follows:

- central neuropathic pain (144 patients), including central post-stroke pain (2 studies) and medical or traumatic spinal cord injury (7 studies);
- peripheral neuropathic pain (95 patients), including peripheral neuropathy (1 study) and radiculopathy (1 study);
- musculoskeletal pain (excluding low back pain) (316 patients), including fibromyalgia (11 studies), myofascial pain (3 studies), and plantar fasciitis (2 studies);
- migraine (265 patients, 8 studies);
- orofacial pain (68 patients), including trigeminal neuralgia (2 studies), temporomandibular disorder (2 studies), and various orofacial pain syndromes (1 study);
- low back pain (266 patients, 5 studies);
- abdominal or pelvic pain (40 patients), including inflammatory bowel syndrome (1 study), endometriosis (1 study), and various types of pelvic pain (3 studies);
- postoperative pain (147 patients, 4 studies);
- miscellaneous syndromes (85 patients), including phantom limb pain (3 studies), multiple sclerosis (1 study), arthralgia (1 study), drug toxicity (1 study), and mixed etiologies (2 studies).

Generally, the tDCS target was M1, the left dorsolateral prefrontal cortex (DLPFC), or the primary visual cortex (V1) for migraine. In most studies, anodal stimulation was applied to M1 of the hemisphere contralateral to pain (in case of focal or lateralized pain) or the dominant (left) hemisphere (in case of more diffuse pain). M1 was usually defined as the location of the C3/C4 electrode in the International 10–20 system for EEG electrode

placement. In the largest (but negative) tDCS study to date in the pain domain, concerning 135 patients with low back pain (Luedtke et al., 2015), the M1 target was rather defined as the motor hotspot of the hand determined by recording abductor digiti minimi MEPs to single-pulse TMS. In almost all studies with the anode intended to be placed over M1 or the left DLPFC, the cathode was positioned over the contralateral supraorbital region. Conversely, in at least five studies, both M1 and DLPFC were stimulated concomitantly or subsequently, or the cathode was positioned in place of the anode over the intended cortical target, including cathodal stimulation of V1 to treat migraine (Antal et al., 2011).

It has been suggested that M1 anodal stimulation may reduce pain by activating various neural circuits present in the precentral gyrus, which would be afferents or efferents that connect structures involved in sensory or emotional component of pain processing, such as the thalamus or the DLPFC, or by facilitating descending pain inhibitory controls (Lefaucheur, 2006; Nguyen et al., 2011). In migraine, cathodal stimulation of V1 is thought to decrease its oversensitivity or increased responsiveness at the origin of headache.

In most studies, stimulation was delivered at an intensity of 2 mA with an electrode size of 35 cm². The duration of the daily stimulation session ranged from 10 min to 20 min, repeated for up to 20 sessions. The effect of a single tDCS session was also assessed in several studies, showing significant pain relief, except in two studies (Luedtke et al., 2012; Dubois et al., 2013). In these latter studies, both anodal and cathodal tDCS of M1 had no impact on acute pain provoked by noxious thermal and electrical stimuli superimposed to chronic low back pain (Luedtke et al., 2012) or postoperative pain in lumbar spine surgery (Dubois et al., 2013). The most commonly used protocol consisted of 20-min anodal stimulation of M1 for five consecutive days, which may lead to significant analgesic after-effects lasting for 2–6 weeks (Fregni et al., 2006e; Valle et al., 2009; Antal et al., 2010; Kim et al., 2013).

A responder is usually defined as a patient experiencing pain relief by more than 30–50% on a visual analogue scale (VAS) (Klein et al., 2015). It is still unclear whether tDCS treatment produces different levels of relief in different types of pain. Analgesic effects of anodal tDCS of M1 have been reported in various neuropathic pain syndromes of either central or peripheral origin, but especially located at the lower limbs (Table 1). Regarding this pain location, analgesic effects of tDCS have been reported in one class II study (Kim et al., 2013) and three class III studies (studies with active group of at least 10 patients, but sham group of less than 10 patients or combining tDCS with another intervention) (Fregni et al., 2006a; Soler et al., 2010; Yoon et al., 2014), but two class II studies did not show any significant difference in pain intensity reduction between active and sham condition (Wrigley et al., 2013; Attal et al., 2016). Finally, one class II study was ambiguous, reporting similar global pain relief after active and sham tDCS, but more responders after active vs. sham tDCS (Souto et al., 2014) (8/10 vs. 3/10). Therefore, we can only propose a recommendation of Level C (possible efficacy) regarding the analgesic effect of anodal tDCS of M1 applied contralaterally to the pain side or on the left hemisphere in patients with neuropathic pain at the lower limbs, at least when pain is secondary to spinal cord lesion. We can further recommend performing tDCS sessions of 20-min duration for at least 5 consecutive days, using 2 mA intensity and 35 cm² electrode size.

In fibromyalgia, a number of publications reported positive results in favor of anodal tDCS of the left M1 or DLPFC, but all coming from a single team, regarding the application of either a classical “bipolar” montage (Fregni et al., 2006e; Roizenblatt et al., 2007; Valle et al., 2009; Mendonca et al., 2011; Riberto et al., 2011) or a presumably more focal, multipolar Laplacian montage (Villamar et al., 2013; Castillo-Saavedra et al., 2016). More recently, three

Table 1
Repeated tDCS session protocols in chronic pain conditions.

Articles	Number and type of patients (protocol design)	Stimulation electrode location	Stimulation intensity, session duration, total number of sessions (protocol duration; follow-up)	Clinical results	Class
<i>Chronic neuropathic pain of the lower limbs due to spinal cord lesion</i>					
Fregni et al. (2006a)	17 patients with traumatic spinal cord injury at various anatomical levels (11 active, 6 sham)	Anode: M1 (C3/C4) of the dominant hemisphere or contralateral to pain side. Cathode: opposite supraorbital region	2 mA, 20 min, 5 sessions (1 week; FU: 16 days)	Pain score reduction (mean: –58%) after active but not sham tDCS at the end of stimulation protocol. No significant pain relief at 16 days. No confounding effect on depression or anxiety	III
Soler et al. (2010)	37 patients with spinal cord injury at various anatomical levels and of various origins (10 active, 9 active + virtual illusion 9 sham, 9 sham + virtual illusion)	Anode: M1 (C3/C4) of the dominant hemisphere or contralateral to pain side. Cathode: opposite supraorbital region	2 mA, 20 min, 10 sessions (2 weeks; FU: 12 weeks)	Greater pain score reduction after active tDCS + virtual illusion, compared to the 3 other groups, up to 12 weeks after stimulation	III
Wrigley et al. (2013)	10 patients with complete spinal cord injury at thoracic level but of various origins (crossover)	Anode: M1 (C3/C4) of the dominant hemisphere. Cathode: opposite supraorbital region	2 mA, 20 min, 5 sessions (1 week; FU: 6 months)	No pain relief after active tDCS	II
Souto et al. (2014)	20 patients with lower limb pain secondary to HTLV-1 infection (10 active, 10 sham)	Anode: left M1 (C3). Cathode: right supraorbital region	2 mA, 20 min, 5 sessions (1 week; no FU)	Similar global pain relief after active and sham tDCS, but more responders >50% pain relief after active vs. sham tDCS (8/10 vs. 3/10)	II
Yoon et al. (2014)	16 patients with traumatic spinal cord injury at various anatomical levels (10 active, 6 sham)	Anode: left M1 (C3). Cathode: right supraorbital region	2 mA, 20 min, 10 sessions (1 week; FU: 1 day)	Pain score reduction (mean –23%) after active tDCS, correlated with metabolic changes in the cerebellum, medulla, anterior cingulate and prefrontal cortices	III
Recommendation: anodal tDCS of left M1 (or contralateral to pain side) is possibly effective in lower limb pain due to spinal cord lesion (Level C)					
<i>Chronic neuropathic pain of the lower limbs due to peripheral nervous system lesion</i>					
Kim et al. (2013)	40 patients with diabetic polyneuropathy (20 active, 20 sham)	Anode: left M1 (C3). Cathode: right supraorbital region	2 mA, 20 min, 5 sessions (1 week; FU: 4 weeks)	Greater pain score reduction (mean –34% vs. –14%) after active vs. sham tDCS, up to 4 weeks after stimulation	II
Attal et al. (2016)	32 patients with unilateral lumbar radiculopathy (21 active, 11 sham)	Anode: M1 (C3/C4) contralateral to pain side. Cathode: opposite supraorbital region	2 mA, 30 min, 3 sessions (1 week; FU: 5 days)	No difference between active and sham tDCS	II
No recommendation for anodal tDCS of left M1 (or contralateral to pain side) in lower limb pain due to peripheral nervous system lesion					
<i>Chronic pain related to temporomandibular disorder</i>					
Donnell et al. (2015)	24 patients (12 active, 12 sham)	Multipolar tDCS. Two anodes: left M1 (C3 + C5). Two cathodes: placed anteriorly (FC3 + FC5)	2 mA, 20 min, 5 sessions (1 week; FU: 1 month)	Increase in the size of pain-free mouth opening one week after tDCS and in the number of responders (>50% pain relief) four weeks after tDCS	III
Oliveira et al. (2015)	32 patients (16 active, 16 sham; combined with cervico-mandibular exercises)	Anode: M1 (C3/C4) contralateral to pain side. Cathode: opposite supraorbital region	2 mA, 20 min, 5 sessions (1 week; FU: 3 weeks)	No difference regarding effect on pain intensity or pressure pain threshold between active and sham tDCS	II
No recommendation for anodal tDCS of left M1 (or contralateral to pain side) in pain related to temporomandibular disorder					
<i>Fibromyalgia</i>					
Fregni et al. (2006e)	21 patients (11 active M1, 10 sham)	Anode: left M1 (C3). Cathode: right supraorbital region	2 mA, 20 min, 5 sessions (1 week; FU: 21 days)	Greater pain score reduction (mean: –58% vs. –33%) and quality of life improvement after active vs. sham tDCS, remaining significant up to 21 days	II
Valle et al. (2009)	28 patients (14 active M1, 14 sham)	Anode: left M1 (C3). Cathode: right supraorbital region	2 mA, 20 min, 10 sessions (2 weeks; FU: 60 days)	Greater pain score reduction (mean: –30% vs. –10%) and quality of life improvement after active vs. sham tDCS, remaining significant up to 60 days	II
Riberto et al. (2011)	23 patients (11 active, 12 sham; combined with a rehabilitation program)	Anode: left M1 (C3). Cathode: right supraorbital region	2 mA, 20 min, 10 sessions (10 weeks (1 session/week); no FU)	More reduced impact of pain on the quality of life after active vs. sham tDCS, but no differential effect on pain intensity, depression, and anxiety	II
Fagerlund et al. (2015)	48 patients (24 active, 24 sham)	Anode: left M1 (C3). Cathode: right supraorbital region	2 mA, 20 min, 5 sessions (1 week; FU: 30 days)	Greater pain score reduction (mean: –14% vs. –2%) and less distress 30 days after active vs. sham tDCS	II
Foerster et al. (2015)	12 patients (crossover)	Anode: left M1 (C3). Cathode: right supraorbital region	2 mA, 20 min, 5 sessions (1 week; FU: 1 week)	Pain score reduction (mean: –35%) after active but not sham tDCS, correlated to glutamatergic transmission in the anterior cingulate	II
Jales Junior et al. (2015)	20 patients (10 active, 10 sham)	Anode: left M1 (C3). Cathode: right supraorbital region	1 mA, 20 min, 10 sessions (10 weeks (1 session/week); FU: 1 week)	Pain score reduction (mean: –40%) and quality of life improvement after active but not sham tDCS	II

(continued on next page)

Table 1 (continued)

Articles	Number and type of patients (protocol design)	Stimulation electrode location	Stimulation intensity, session duration, total number of sessions (protocol duration; follow-up)	Clinical results	Class
Cummiford et al. (2016)	13 patients (crossover)	Anode: left M1 (C3). Cathode: right supraorbital region	2 mA, 20 min, 5 sessions (1 week, no FU)	No difference in pain score reduction between active and sham tDCS but differences in functional cerebral connectivity changes assessed by fMRI	III

Recommendation: Anodal tDCS of left M1 is probably effective to relieve pain in fibromyalgia patients (Level B)

FU: follow-up; HTLV-1: Human T-lymphotropic virus type 1; M1: primary motor cortex.

additional class II studies were published by independent teams, showing a greater pain relief produced by anodal stimulation of the left M1 compared to sham tDCS (Fagerlund et al., 2015; Foerster et al., 2015; Jales Junior et al., 2015). Overall, these studies reported a mean reduction of pain intensity ranging between 14% and 58% compared to baseline at the end of the tDCS protocol (5–10 sessions), which remained statistically significant up to one or two months after the end of the intervention. Short-lasting effects that were not prolonged for more than one week after 5 days of 1 mA anodal tDCS were observed in patients with focal myofascial pain in the shoulder (Sakrajai et al., 2014). Pain relief was associated with an improvement in the quality of life in most tDCS studies of patients with fibromyalgia syndrome. Therefore, a recommendation of Level B (probable efficacy) can be proposed regarding the analgesic effect of anodal tDCS of the left M1 in fibromyalgia. However, the clinical relevance of the intensity of pain relief induced by anodal tDCS of the left M1 in this condition is clearly debated (Fagerlund et al., 2015). A recent open-label trial showed a clinically significant benefit (50% pain reduction associated with quality of life improvement) in 7/14 patients treated for 6 weeks by tDCS delivered over M1 using a multipolar Laplacian montage (Castillo-Saavedra et al., 2016), but these results remain to be replicated by other teams independently. It is also important to determine whether the analgesic effects of tDCS in fibromyalgia syndrome can be distinguished from potential concomitant effects on depression and anxiety. Finally, we have no practical guidelines on how to design a maintenance protocol for providing long-term therapeutic effects of tDCS in this chronic disease.

In other pain conditions, there are no replicated convincing studies showing beneficial effects of tDCS applied to M1 or the left DLPFC provided by independent teams and therefore, no recommendation can be made. For example, there are only single positive studies regarding the value of repeated sessions of anodal tDCS of M1 contralateral to pain in trigeminal neuralgia (Hagenacker et al., 2014), pain related to multiple sclerosis (Mori et al., 2010), or irritable bowel syndrome (Volz et al., 2016). In pain related to temporomandibular disorder, one study using multipolar montage (2 cathodes and 2 anodes) reported beneficial effects (Donnell et al., 2015), whereas no difference was found in pain relief between active and sham condition in another study using a more classical bipolar tDCS montage with the anode over M1 (Oliveira et al., 2015). In chronic low back pain, the two published studies using repeated sessions of anodal tDCS of M1 were negative, the first one being based on a very small sample size (8 patients, therefore not retained in the analysis) (O'Connell et al., 2013), but the other one (Luedtke et al., 2015) including the largest series to date (135 patients) about tDCS studies in the pain domain.

With regard to other conditions, most studies had methodological limitations, such as small sample size or single-session design. For example, in a small group of patients, a single session of anodal tDCS of the left DLPFC performed just after endoscopic retrograde cholangiopancreatography was found to reduce pain intensity

and morphine consumption after intervention (Borckardt et al., 2011). However, a subsequent study showed that a similar protocol (but with a different cathode placement) was unable to replicate these results in a larger series of patients undergoing gastric bypass surgery (Dubois et al., 2013). Later, in two studies, the group of Borckardt et al. reported the efficacy of a tDCS protocol consisting of four 20-min sessions performed from the immediate postoperative time to the day after surgery, with the anode over a region close to the leg area of the motor cortex (C1/C2 or Cz electrode site) and the cathode over the right DLPFC (F4 electrode site) in series of 39 patients undergoing total knee arthroplasty (Borckardt et al., 2013) and 27 patients undergoing lumbar spine procedure (Glaser et al., 1976). In both studies, tDCS was able to reduce postoperative opioid requirements. These results still remain to be replicated by another group.

In some indications, the value of the left DLPFC target was compared to that of M1 in terms of analgesic efficacy. The results were either similar (Valle et al., 2009) or in favour of M1, e.g., in patients with fibromyalgia (Fregni et al., 2006e) or diabetic polyneuropathy (Kim et al., 2013).

Finally, regarding migraine, the first positive results were reported by using cathodal tDCS of V1 (Antal et al., 2011; Wickmann et al., 2015). Other positive results were reported using anodal tDCS of M1 in two studies. One study included more than 10 patients receiving active tDCS and showed a reduction in pain intensity, number of attacks, and medication at the end of the intervention and up to 8 weeks after active tDCS (Auvichayapat et al., 2012). However, the other study was a preliminary report of results obtained in 8 patients, in which a reduction in the intensity of pain and the duration of migraine episodes was only observed in a delayed follow-up (Dasilva et al., 2012). Therefore, no recommendation can be made for this indication.

As a conclusion, the present level of evidence for the analgesic effect of M1 stimulation is weaker for tDCS than for rTMS (Lefaucheur et al., 2014). However, regarding this comparison, the most striking point is the fact that the best level of evidence for tDCS efficacy were found in different indications (fibromyalgia and neuropathic pain in the lower limbs) from that of M1 rTMS, which is known to be more prone to relieve chronic neuropathic pain at the face or upper limbs (Lefaucheur et al., 2004, 2006). One may speculate that tDCS and rTMS, although targeting the same motor cortical region, do not produce pain relief through the same mechanisms of action. This hypothesis is reinforced by the report of a patient with chronic refractory neuropathic pain who did not respond to high-frequency rTMS of M1, but was subsequently improved by repeated sessions of anodal tDCS of M1 in the long term (Hodaj et al., 2016). It has been suggested that rTMS might activate similar networks as epidural motor cortex stimulation (Lefaucheur et al., 2010), of which analgesic effect is obtained according to the placement of cathode(s) over the precentral gyrus (Holsheimer et al., 2007a,b), in contrast to tDCS for which the precentral electrode is classically an anode. In addition, the intensity of rTMS and epidural stimulation is sufficient to elicit additional

action potentials in the activated circuits, whereas tDCS is assumed to modulate spontaneous firing (Lefaucheur, 2012). Thus, different mechanisms of action might subserve different indications for high-frequency rTMS and anodal tDCS of M1 in the pain domain. Only one sham-controlled study directly compared the analgesic efficacy of these two approaches (Attal et al., 2016). This study included patients with neuropathic pain due to lumbosacral radiculopathy and showed that high-frequency rTMS, but not anodal tDCS of M1 contralateral to the painful area (three daily sessions) was superior to sham stimulation. This result is surprising, since, as mentioned above, relief of neuropathic pain in the lower limbs was more frequently reported after tDCS than after rTMS in the literature. Finally, as an alternative in the treatment of refractory chronic pain, tDCS offers various advantages compared to rTMS, e.g., a low-cost equipment that can be used at home, as shown in a recent case report of long-term treatment of myofascial pain using a tDCS protocol controlled by tele-medicine (Pérez-Borrego et al., 2014). Sham-controlled protocols of repeated tDCS sessions performed at home by the patients themselves are currently under investigation (O'Neill et al., 2015).

4. Parkinson's disease

In advanced Parkinson's disease (PD), the emergence of fluctuations, dyskinesias, difficulties with gait and postural control, cognitive impairment and non-motor symptoms refractory to conventional therapy poses therapeutic challenges. The success of deep brain stimulation (DBS) and advances in the understanding of the pathophysiology of PD have raised interest in NIBS techniques as alternative therapeutic tool. The rationale for the use of NIBS draws from the concept that reversing abnormalities in brain activity and physiology thought to cause the clinical deficits may restore normal functioning. Currently the best evidence in support of this concept comes from DBS, which improves motor deficits, and modulates brain activity and motor cortex physiology, though whether a causal interaction exists remains largely undetermined. At present, tDCS offers a safe, easy-applicable method of NIBS, and there are now several published tDCS trials aimed at improving various clinical aspects in the domain of PD (Benninger and Hallett, 2015; Elsner et al., 2016b).

Actually, a PubMed search (keywords: tDCS AND Parkinson's disease) identified 72 papers, including 15 original clinical studies and 225 patients. One paper was a single case report (Kaski et al., 2014a), whereas 10–25 patients were included in the other studies. The objectives of these studies performed in parkinsonian patients were various and can be summarized as follows:

- to study the effect of tDCS preconditioning (priming protocol, 1 mA for 10 min) on the ability of a subsequent low-frequency rTMS protocol (1 Hz, 900 pulses) delivered over M1 to improve motor performance, motor control, or gain kinematics (Grüner et al., 2010; Eggers et al., 2012; Von Papen et al., 2014);
- to study the effect of anodal tDCS of the left DLPFC on working memory (Boggio et al., 2006) or verbal fluency (Pereira et al., 2013);
- to study the effect of anodal tDCS of the left or right DLPFC on executive or cognitive functions (Doruk et al., 2014; Manenti et al., 2016);
- to study the effect of anodal tDCS of the left and right DLPFC on walking abilities (Manenti et al., 2014);
- to study the effect of anodal tDCS over various motor regions on gait and motor performance (Verheyden et al., 2013; Kaski et al., 2014a,b; Valentino et al., 2014; Costa-Ribeiro et al., 2016; Ferrucci et al., 2016), optionally combined with prefrontal stimulation (Benninger et al., 2010).

4.1. tDCS effects on motor symptoms

In the literature, there are only three sham-controlled therapeutic tDCS trials based on repeated sessions of tDCS delivered over the motor cortex and including at least 10 PD patients in the active tDCS condition: two were parallel-designed and the other crossover-designed randomized controlled trials (RCTs) (Table 2).

In one parallel-designed RCT (Benninger et al., 2010), the safety and efficacy of anodal tDCS applied to the motor and prefrontal cortices in 8 sessions over 2.5 weeks were investigated. tDCS exerted significantly beneficial effects on gait (10 m walking) and bradykinesia (assessed by a timed testing of sequential hand and arm movements) for the follow-up period of 3 months. However, the observed effects were small and still need to be confirmed in a larger study. Conversely, changes in the motor score of the Unified Parkinson's Disease Rating Scale (UPDRS), reaction time, physical and mental well-being, and self-assessed mobility did not differ between tDCS and sham intervention.

In a crossover RCT (Valentino et al., 2014), a protocol of 5 sessions of anodal tDCS of M1 was found to provide a beneficial effect on gait, freezing of gait, and motor performance in 10 parkinsonian patients. These effects lasted for the follow-up period of 1 month. The long-lasting persistence of effects in the both RCTs points out to plasticity phenomena. In the context of PD, it is important to note that dopamine, in a complex balance between D1 and D2 receptor mediation, exerts dose-dependent consolidation-enhancing effects on tDCS-induced changes of excitability and NMDA receptor-mediated neuroplasticity in the human motor cortex (Nitsche et al., 2006, 2009a; Fresnoza et al., 2014). In a recent study based on a small sample of 9 patients, anodal tDCS applied bilaterally over M1 for five consecutive days was found to improve levodopa-induced dyskinesias, but not other motor symptoms (Ferrucci et al., 2016). Anodal cerebellar tDCS provided the same results as M1 tDCS.

In addition, beyond the proper effects of tDCS on motor control and cortical excitability, there is increasing evidence pointing to the enhancement of motor learning and long-term retention as the rationale for combining tDCS protocol with rehabilitative intervention in PD patients (Benninger et al., 2010). This approach is supported by data obtained in healthy subjects (Nitsche et al., 2003c; Reis et al., 2009) and it was first applied to promote motor recovery in stroke patients (Hummel et al., 2005). In PD, this was the subject of two recent studies. They showed prolonged improvement in gait or motor abilities following anodal tDCS over the lower limb motor/supplementary motor area combined with cueing gait training (Costa-Ribeiro et al., 2016a,b) or anodal tDCS over the DLPFC contralateral to the most affected body side combined with physical therapy (Manenti et al., 2016).

Acute effects of single tDCS sessions have also been reported in PD patients. In a crossover study, a single session of anodal tDCS of left M1, but not of cathodal tDCS of left M1 or anodal tDCS of left DLPFC, was found to improve motor function (UPDRS score and simple reaction time) (Fregni et al., 2006d). In another crossover study, a single session of anodal tDCS of M1 of the dominant hemisphere reduced the time to walk 10 m, but had no effects on other gait measures (Verheyden et al., 2013). Gait velocity was also found to be improved after a single session of anodal tDCS of a region roughly corresponding to lower limb motor region with the cathode positioned at theinion (Kaski et al., 2014a,b).

4.2. tDCS effects on nonmotor symptoms

Cognitive impairment is prevalent in advanced PD and a major cause of disability and institutionalization, but fronto-executive dysfunction may manifest early. In a crossover study including

Table 2
Repeated tDCS session protocols in motor symptoms of Parkinson's disease.

Articles	Number and type of patients (protocol design)	Stimulation electrode location	Stimulation intensity, session duration, total number of sessions (protocol duration; follow-up)	Clinical results	Class
Benninger et al. (2010)	25 patients (HY 2–4) (13 active, 12 sham)	Anode: both (pre)motor and prefrontal cortices. Cathodes: mastoids	2 mA, 20 min, 8 sessions (2.5 weeks; FU: 3 months)	Improvement of gait in off-condition for a short time and of bradykinesia in on- and off-conditions, persisting at least 3 months after the stimulation period	II
Valentino et al. (2014)	10 patients (HY 2.5–4) (crossover)	Anode: M1 (leg area) contralateral to dominant lower limb. Cathode: opposite supraorbital region	2 mA, 20 min, 5 sessions (1 week; FU: 1 month)	Improvement of motor performance (motor UPDRS) and gait, with reduction in number and duration of freezing episodes, persisting at least 4 weeks after the stimulation period	III
Costa-Ribeiro et al. (2016a,b)	22 patients (HY 1–3) (11 active, 11 sham), combined with cueing gait training	Anode: 2 cm anterior to Cz. Cathode: supraorbital region opposite to the most affected side	2 mA, 20 min, 10 sessions (3 weeks; FU: 1 month)	Improvement of motor performance and gait due to gait training was similar between the active and sham tDCS groups, but the clinical gain and a decrease in motor threshold lasted one month only in the active group	II

No recommendation for anodal tDCS of the motor cortex in motor symptoms of Parkinson's disease.

FU: follow-up; HY: Hoehn and Yahr disease stage; M1: primary motor cortex; UPDRS: Unified Parkinson's Disease Rating Scale.

18 PD patients, a single session of anodal tDCS of left DLPFC, but not of left M1, improved performance in a working memory task, only at the stimulation intensity of 2 mA (Boggio et al., 2006). In another crossover study including 16 PD patients, a single session of anodal tDCS improved verbal fluency, associated with large-scale functional changes between connected brain areas, more significantly when the stimulation was applied to the left DLPFC than to the left temporo-parietal cortex (TPC) (Pereira et al., 2013). Finally, in a sham-controlled study of 20 PD patients with parallel-arm design, a protocol of 10 sessions of anodal tDCS delivered over the DLPFC contralateral to the most affected body side during a physical therapy program was found to increase cognitive performance and verbal fluency only in the active arm group (Manenti et al., 2016). The cognitive improvement was significantly lasting at 3-month follow-up, while an improvement in motor abilities and a reduction of depressive symptoms was similarly observed in both active and sham groups at the end of the treatment.

4.3. Conclusion

The currently published studies suggest a potential impact of anodal tDCS of M1 on gait and motor symptoms in PD patients, but do not provide sufficient evidence for a recommendation, because of heterogeneity in the targeted motor area or the outcome measures, for example. The clinical effects reported so far appeared to be negligible regarding functional independence and quality of life. Other results concerned small series of patients and mostly single-session protocols with short-lasting effects. Various montages and designed cortical targets remain to be investigated in larger studies. Combined approaches of tDCS with a rehabilitative intervention or priming strategies may potentiate the therapeutic efficacy (Benninger and Hallett, 2015). There is also a need to evaluate the value of tDCS protocols to act on nonmotor parkinsonian symptoms at a clinically meaningful level.

5. Other movement disorders

Actually, published tDCS studies on movement disorders other than PD are rare and have been recently reviewed (Ferrucci et al., 2016). There are only two sham-controlled crossover studies using repeated tDCS sessions. The first study concerned 8 patients with essential tremor who completed a tDCS protocol for 10 days with two cathodes placed over both cerebellar hemispheres and two

anodes positioned over both prefrontal areas (Gironell et al., 2014). In this study, any short- or long-lasting clinical benefits in any outcome measure was observed after active stimulation compared to the sham condition. The second study was a case report of 2 patients with Tourette's syndrome who benefitted from a 5-day protocol of cathodal tDCS of left M1 (with the anode over the right deltoid muscle) (Mrakic-Sposta et al., 2008). Active stimulation significantly decreased the number of motor and phonic tics in both patients at the end of the 5-day treatment.

It is for dystonia that there would be more relevance to find tDCS studies. Indeed, dystonia is a heterogeneous disorder characterized by impaired motor control related to a loss of inhibition, sensory dysfunction, and alterations of synaptic plasticity leading to abnormal sensorimotor integration (Quartarone and Hallett, 2013). Clinical evidence support efficacy of DBS, whereas beneficial effects of NIBS, if any, are modest and short-lasting (Benninger et al., 2015; Cho and Hallett, 2016). Regarding tDCS and dystonia, a PubMed search (keywords: tDCS AND dystonia) identified 32 papers, including 15 original clinical studies and 147 patients. Thus, the amount of published data is not far from that of PD. However, most studies are case reports or small case series. Approximately only half of the studies included at least 10 patients. In addition, the studies were often issued from the same group, for specific clinical conditions, which were:

- musician's dystonia (77 patients; 7 studies);
- writer's cramp (35 patients; 4 studies);
- cervical dystonia (2 patients; 2 studies);
- pediatric cases of primary and secondary generalized dystonia or hemidystonia, including secondary to cerebral palsy (33 patients; 3 studies).

Regarding studies using repeated tDCS sessions, we found:

- a series of 30 musicians with right-hand primary focal dystonia who received 10 sessions of tDCS delivered over the both M1 regions (C3/C4, the cathode being on the left side), combined with a rehabilitative intervention (sensory motor retuning therapy) for 2 weeks and who experienced a more significant improvement of their dystonia severity score after active than sham tDCS (Rosset-Llobet et al., 2015). Interestingly, another research group reported that single-session protocols of anodal or cathodal tDCS of left M1 (with right supraorbital cathode) failed to produce any beneficial effects in patients with musi-

cian's dystonia (Buttkus et al., 2010, 2011), whereas simultaneous bihemispheric ("dual") stimulation of M1 (left cathode + right anode) improved the rhythmic accuracy of sequential finger movements in such patients, up to 4 days after intervention (Furuya et al., 2014);

- a series of 8 patients with writer's cramp who underwent 3 tDCS sessions in one week, with the cathode placed over the TMS motor hotspot and the anode on the contralateral mastoid (Benninger et al., 2011). The stimulation did not produce beneficial effects on disability and severity of dystonic symptoms and failed to restore normal kinematics of handwriting and cortical inhibition. Sham-stimulated patients even reported a significantly better improvement contrasting with the subjective worsening with tDCS in some patients, which remained unexplained and constituted the reason for the premature termination of the study;
- the case of one patient with cervical dystonia who was not improved by five consecutive daily sessions of tDCS with the cathode at C4 and the anode at P3, according to the international 10/20 EEG electrode system (Angelakis et al., 2013);
- another case of one patient with cervical dystonia who benefited on dystonia symptoms and quality of life from a sequential protocol of anodal tDCS of the both cerebellar hemispheres and the right M1 performed during 20 sessions over 12 weeks after a botulinum toxin injection (Bradnam et al., 2014);
- and finally a series of 9 young people with mainly generalized dystonia secondary to cerebral palsy who did not respond to a clinically meaningful extent to a 5-day protocol of either cathodal or anodal tDCS of M1 (2 mA, 9 min per day) (Bhanpuri et al., 2015).

All these studies are not-replicated studies, based on small sample sizes, excepting the study published by Rosset-Llobet et al. (2015). Therefore, no recommendation can be drawn from these results regarding the efficacy of any tDCS protocol on dystonia symptoms.

6. Motor stroke

The recovery of motor function after stroke is one of the most important issues addressed in neurorehabilitation medicine. The rationale of cortical stimulation following stroke is to promote adaptive neuroplasticity, taking place in the perilesional region as well as in the homologous area of the contralesional hemisphere. Functional magnetic resonance imaging (fMRI) studies have revealed an initial decrease in ipsilesional activity in the first 3 days after stroke followed by an increase in activity in homologous contralesional as well as perilesional areas after 10 days (Grefkes and Ward, 2014). Contralesional activity returns close to normal values when motor function improves but remains elevated when significant clinical impairment persists. The initially reduced ipsilesional activity is associated with a decreased ipsilesional corticospinal excitability as indicated by increased motor threshold and decreased MEP amplitude when tested by TMS. This leads to a contralesional increase in corticospinal excitability due to diminished interhemispheric inhibition from ipsilesional to contralesional M1, which in turn increases interhemispheric inhibition from contralesional to ipsilesional M1 and further decreases ipsilesional corticospinal excitability (Traversa et al., 1998; Murase et al., 2004). Thus, tDCS therapy aims at either increasing ipsilesional M1 excitability or decreasing contralesional M1 excitability, or both at the same time via bihemispheric tDCS. Most tDCS studies targeted the hand/arm M1 representation, but some studies specifically addressed post-stroke swallowing or lower limb dysfunction. Studies differed in stimulation parameters (tDCS intensity, polarity and

duration), in the number of sessions applied, the duration of follow-up, and the tasks performed for outcome evaluation. Finally, tDCS can be used alone or combined in different sequence order with physical or other non-pharmacological rehabilitation therapies.

A PubMed research (keywords: tDCS AND motor AND stroke) identified 261 papers, including 68 original clinical trials and 1,032 patients. The majority of these studies targeted upper limb function. As for the other indications, we excluded from the analysis all studies that do not have a control condition using sham tDCS, a sample size with at least 10 patients receiving active tDCS, and a design consisting of repeated daily sessions. According to these criteria, we retained only 7 studies for making recommendations on the value of tDCS to improve post-stroke motor dysfunction (Table 3).

Two large RCTs, fulfilling the criteria for class I, did not show any significant clinical effect of tDCS on motor function recovery (Hesse et al., 2011; Rossi et al., 2013). Presumably, in one study (Hesse et al., 2011), this was due to the inclusion of patients with cortical stroke and severe motor weakness, who are less susceptible to improve after cortical stimulation (Ameli et al., 2009). The second negative study (Rossi et al., 2013) concerned the immediate acute phase (two days after stroke) by applying anodal tDCS to the ipsilesional M1, whose dramatic reduction in activity in this period (Grefkes and Ward, 2014) may likely not be overcome by tDCS.

The other controlled studies retained in our analysis were of class II (Table 3), reporting either positive or negative results in terms of efficacy of tDCS on motor recovery or quality of life. There is heterogeneity in clinical profile of the population, tDCS methodology, or outcome measures, precluding robust conclusions. For example, regarding anodal tDCS of ipsilesional M1 in chronic stroke patients, leg area was targeted and walking measures were performed in one negative study (Geroïn et al., 2011), while hand area was targeted in two positive studies, one showing improvement in quality of life but not in motor performance (Viana et al., 2014) and the other showing improvement in some motor tests but not all (Allman et al., 2016). Overall, the level of evidence remains insufficient to make any recommendation regarding either anodal tDCS of ipsilesional M1 or cathodal tDCS of contralesional M1 in populations of patients at various time after stroke.

A previous meta-analysis of anodal tDCS of ipsilesional M1 in chronic stroke patients, including trials with smaller sample sizes and based on single tDCS sessions, showed small to moderate effect sizes for the improvement of upper limb function when compared with baseline or sham tDCS, respectively (Butler et al., 2013). The same year, another meta-analysis (Elsner et al., 2013b) including all types of tDCS protocols, found evidence of an effect in favour of tDCS on activities of daily living (primary outcome) at follow-up but not at the end of the intervention phase in stroke patients. The reverse was observed for upper limb motor function, but evidence was of low quality when only studies with low risk of bias were considered. This meta-analysis was updated three years later (Elsner et al., 2016c): the moderate beneficial effect on activities of daily living was found both at the end of the intervention and at follow-up, whereas no more evidence for upper limb motor function improvement could be observed. Another meta-analysis including multiple- and single-session studies combining tDCS and motor training of the upper extremities showed moderate long-term effects on motor learning after either anodal tDCS of ipsilesional M1, cathodal tDCS of contralesional M1, or bihemispheric stimulation of M1 in the postacute or chronic stage of post-stroke recovery (Kang et al., 2016). A fourth meta-analysis, including only RCTs with a multiple-session design, showed only small non-significant beneficial effects of therapeutic strategies combining tDCS and rehabilitation programs for poststroke upper extremity recovery (Tedesco Triccas et al., 2016). A fifth

Table 3
Repeated tDCS session protocols in motor stroke.

Articles	Number and type of patients (protocol design)	Stimulation electrode location	Stimulation intensity, session duration, total number of sessions (protocol duration; follow-up)	Clinical results	Class
Anodal stimulation of the ipsilesional motor cortex					
<i>Acute phase</i>					
Rossi et al. (2013)	50 patients (2 days after stroke) (25 active, 25 sham)	Anode: ipsilesional M1 (C3/C4). Cathode: opposite supraorbital region	2 mA, 20 min, 5 sessions (1 week; FU: 3 months)	No difference in motor or daily living changes (FMA, NIHSS, mRS, BI) after active vs. sham tDCS at the end of the intervention and 3 months later	I
Sattler et al. (2015)	20 patients (1–14 days after stroke) (10 active, 10 sham; combined with 5 Hz radial nerve stimulation)	Anode: ipsilesional M1 (TMS hotspot). Cathode: opposite supraorbital region	1.2 mA, 13 min, 5 sessions (1 week; FU: 1 month)	Improvement of upper limb motor performance (JHFT, but not FMA) after anodal vs. sham tDCS at 2 and 4 weeks after intervention	II
<i>Postacute phase</i>					
Hesse et al. (2011)	56 patients (3–8 weeks after stroke) (28 active, 28 sham; combined with robot-assisted arm motor training)	Anode: ipsilesional M1 (C3/C4). Cathode: opposite supraorbital region	2 mA, 20 min, 30 sessions (6 weeks; FU: 3 months)	No difference in motor or daily living changes (FMA, BBT, MRC, mAS, BI) after active vs. sham tDCS at the end of the intervention and 3 months later	I
Khedr et al. (2013)	27 patients (1–4 weeks after stroke) (14 active, 13 sham; combined with conventional physical therapy)	Anode: ipsilesional M1. Cathode: opposite supraorbital region	2 mA, 25 min, 6 sessions (1 week; FU: 3 months)	Improvement of four limb motor performance and daily living activities (OMCASS, BI), correlated with MT reduction after active vs. sham tDCS at the end of the intervention and 3 months later	II
Chang et al. (2015)	24 patients (1–4 weeks after stroke) (12 active, 12 sham; combined with robot therapy for upper limb)	Anode: ipsilesional M1 (leg area, TMS hotspot). Cathode: opposite supraorbital region	2 mA, 10 min, 10 sessions (2 weeks; FU: 1 day)	Improvement of lower limb motor performance (FMA), MEP facilitation, but no effect on gait after anodal vs. sham tDCS	II
<i>Chronic phase</i>					
Geroin et al. (2011)	20 patients (14–34 months after stroke) (10 active, 10 sham; combined with robot-assisted gait training)	Anode: ipsilesional M1 (leg area). Cathode: opposite supraorbital region	1.5 mA, 7 min, 10 sessions (2 weeks; FU: 2 weeks)	No difference in walking tests after active vs. sham tDCS	II
Viana et al. (2014)	20 patients (14–52 months after stroke) (10 active, 10 sham; combined with virtual reality therapy)	Anode: ipsilesional M1 (C3/C4). Cathode: opposite supraorbital region	2 mA, 13 min, 15 sessions (5 weeks; no FU)	Improvement of quality of life (SSQOL) but no difference in motor performance (FMA, WFMT, mAS) after active vs. sham tDCS	II
Allman et al. (2016)	24 patients (6–141 months after stroke) (11 active, 13 sham; combined with motor training)	Anode: ipsilesional M1 (C3). Cathode: opposite supraorbital region	1 mA, 20 min, 9 sessions (2 weeks; FU: 3 months)	Improvement of motor performance on ARAT and WFMT but not on upper extremity FMA after active vs. sham tDCS at the end of the intervention and 3 months later	II
No recommendation for anodal tDCS of the ipsilesional motor cortex in motor stroke					
Cathodal stimulation of the contralesional motor cortex					
<i>Postacute phase</i>					
Hesse et al. (2011)	57 patients (3–8 weeks after stroke) (29 active, 28 sham; combined with robot-assisted arm motor training)	Anode: opposite supraorbital region. Cathode: contralesional M1 (C3/C4)	2 mA, 20 min, 30 sessions (6 weeks; FU: 3 months)	No difference in motor or daily living changes (FMA, BBT, MRC, mAS, BI) after active vs. sham tDCS at the end of the intervention and 3 months later	I
Khedr et al. (2013)	26 patients (1–4 weeks after stroke) (13 active, 13 sham; combined with conventional physical therapy)	Anode: opposite supraorbital region. Cathode: contralesional M1	2 mA, 25 min, 6 sessions (1 week; FU: 3 months)	Improvement of four limb motor performance and daily living activities (OMCASS, BI), correlated with MT reduction after active vs. sham tDCS at the end of the intervention and 3 months later	II

No recommendation for cathodal tDCS of the contralesional motor cortex in motor stroke.

ARAT: action research arm test; BBT: box and block test; BI: Barthel Index; FMA: Fugl-Meyer assessment; FU: follow-up; JHFT: Jebsen hand function test; mAS: modified Ashworth scale; MEP: motor evoked potential; MRC: Medical Research Council score; mRS: modified Rankin scale; NIHSS: National Institute of Health stroke score; OMCASS: Orgogozo's MCA scale; SSQOL: stroke specific quality of life scale; TMS: transcranial magnetic stimulation; WFMT: Wolf Motor Function Test.

meta-analysis determined whether the outcome of tDCS of M1 in poststroke motor recovery has a dose–response relationship (Chhatbar et al., 2016). This study included 8 sham-controlled RCTs based on repeated tDCS sessions (≥ 5) including assessment on the Fugl-Meyer Assessment (FMA) scale, concerning a total of 213 stroke patients. This study showed a moderate effect of active stimulation on FMA scores with greater effects of bihemispheric stimulation and in chronic stroke patients. It further revealed a

positive dose–response relationship for current and charge density as well as a negative dose–response relationship for electrode size.

Additionally, some results obtained with single tDCS sessions are worth being discussed, although they should be considered as “proof-of-concept” studies, based on immediate or short-lasting effects rather than “therapeutic trials” aimed at producing sustained effects, which could be clinically relevant. In chronic

stroke, several single-session studies showed beneficial effects of contralesional cathodal stimulation of M1 on motor performance of the paretic hand, e.g., assessed by the Jebsen–Taylor hand function test (JTT) (10 patients investigated 1–16 months after stroke in Mahmoudi et al., 2011) or a finger movement task (12 patients investigated 12–64 months after stroke in Zimerman et al., 2012). Short-lasting motor performance improvement was also reported after a single session of ipsilesional anodal stimulation of M1, e.g., regarding pinch force and motor response time of the paretic hand (11 patients investigated 18–107 months after stroke in Hummel et al., 2006; 13 patients investigated 18–70 months after stroke in Stagg et al., 2012). One study showed that tDCS effects were greater after ipsilesional anodal stimulation of M1 than contralesional cathodal stimulation (Stagg et al., 2012).

A single anodal tDCS session targeted over the leg area of ipsilesional M1 was also found to improve gait and lower limb strength in a series of 11 patients in the postacute phase (1–3 months after stroke) (Sohn et al., 2013). The same montage was used in a multiple-session study, showing some improvement of motor function in the lower limbs, but not of gait performance (Chang et al., 2015). Another study, still using the same tDCS protocol but combined with robot-assisted gait training for 10 sessions in patients with chronic stroke (14–34 months after stroke) did not confirm the additional value of anodal tDCS targeted over the leg area of ipsilesional M1 to improve walking abilities (Geroïn et al., 2011). The absence of additional value of tDCS when combined with robot therapy was confirmed for upper extremity rehabilitation, evaluated on FMA scale in a recent study (Triccas et al., 2015). In this study, 18 sessions of ipsilesional anodal tDCS were performed over 8 weeks in a series of 22 patients either in the postacute (2–3 months after stroke) or chronic phase (9–90 months after stroke). Both active and sham tDCS groups included only 6 postacute stroke patients and 5 chronic stroke patients. Because of this heterogeneity and small sample size, the study was not entered into the analysis for grading. These negative results probably revealed a ceiling effect of very thorough rehabilitation programs. Conversely, tDCS was found to be more beneficial than basic functional training for improving upper and lower limb functions in a parallel-arm study of 20 chronic stroke patients receiving ipsilesional anodal tDCS, 5 days a week for 4 weeks (Cha et al., 2014).

All above cited results were obtained with the “return” (“reference”) tDCS electrode placed over the contralateral supraorbital region. Conversely, some studies also considered bihemispheric stimulation of M1, with the cathode over the contralesional M1 region and the anode over the lesioned M1. One single-session study showed that bilateral montage was as efficacious as unilateral cathodal or anodal stimulation (Mahmoudi et al., 2011). Also in proof-of-concept studies based on a single session, one group showed the value of bihemispheric M1 tDCS protocol combined with a visuomotor skill learning task (Lefebvre et al., 2012) or precision grip and dexterity tests (Lefebvre et al., 2014) to enhance motor rehabilitation in chronic stroke patients. However, another study did not confirm the value of a single bihemispheric tDCS session on walking abilities in a small series of chronic stroke patients (van Asseldonk and Boonstra, 2016). To our knowledge, there is only one study reporting the clinical impact of a 5-day protocol of bihemispheric M1 tDCS, combined with 60-min occupational therapy, in a series of 20 patients with chronic stroke (5–81 months after stroke) (Lindenberg et al., 2010). In this parallel-arm study, an improvement of motor performance on FMA and Wolf motor function test (WMFT), lasting for one week beyond the time of stimulation, was observed in the 10 patients having received active tDCS. However, in the absence of replicated bihemispheric tDCS studies including repeated sessions, no recommendation can be proposed for this approach. In addition, the

superiority of unilateral anodal and cathodal M1 stimulation over bilateral M1 stimulation was only shown regarding the effect of tDCS on motor corticospinal excitability in healthy volunteers or speeding reaction time in chronic stroke patients (O’Shea et al., 2014). The potential impact of bihemispheric M1 tDCS on motor rehabilitation may depend on the microstructural and functional status of transcallosal motor tracts (Lindenberg et al., 2016). However, the concept of a bihemispheric stimulation leading to enhance the excitability of the lesioned motor cortex by the anode and to reduce the excitability of the contralesional hemisphere by the cathode remains to be demonstrated. In particular, a “titration” study is needed for bihemispheric versus monohemispheric stimulation of M1 (Batsikadze et al., 2013), to determine the respective impact on motor cortex excitability of these two montages, according to the resulting changes in MEP size, for example.

In the present work, we have differentiated the results according to the time window following stroke, which is known to be a crucial parameter in the focal changes of brain excitability and plasticity. The time of the intervention after stroke onset has very likely significant impact on the efficacy of a given tDCS paradigm. In the acute phase of stroke, a beneficial effect of cathodal tDCS to reduce the inhibitory action exerted by the contralesional M1 onto the lesioned hemisphere should be expected. However, the adaptive role of the contralesional hemisphere in stroke recovery remains controversial (Di Pino et al., 2014). As mentioned above, the classical concept of interhemispheric competitive rivalry supports the objective of decreasing the excitability of the contralesional motor cortex and its ability to further reduce the neural activities in the lesioned hemisphere (Marshall et al., 2000; Ward et al., 2003; Murase et al., 2004). Conversely, some fMRI studies showed a positive correlation between the gain after rehabilitation therapy and the level of cortical activation in the contralesional hemisphere (Cramer et al., 1997; Johansen-Berg et al., 2002a). Furthermore, one study showed that the improvement in motor function and dexterity of stroke patients receiving anodal tDCS over the lesioned motor cortex were associated with an increase in the excitability of the contralesional rather than the ipsilesional hemisphere (Cunningham et al., 2015). In fact, the beneficial contribution of contralesional hemispheric activation in motor performance of the paretic limb might primarily result from the involvement of premotor rather than primary motor areas (Caramia et al., 2000; Johansen-Berg et al., 2002b). In addition, the influence of inhibitory projections from the contralesional brain areas to the spinal cord depends on the considered motor region (either proximal or distal limb muscles), the degree of functional impairment, and the extent of the neuronal damage.

Indeed, the most important factor for predicting brain stimulation efficacy in motor stroke seems to be the integrity of the stimulated cortical region and the corresponding corticospinal tract, as assessed by MEP recordings (Talelli et al., 2006; van Kuijk et al., 2009) or neuroimaging methods (Riley et al., 2011; Bradnam et al., 2012). When the pyramidal motor structures are rather preserved in mildly to moderately affected patients, inhibition of contralesional M1 by cathodal tDCS may promote stroke recovery at least in the post-acute and chronic phases. When neuronal destruction is more extensive in moderately to severely affected patients, descending projections from the contralesional hemisphere contribute to recovery and cathodal tDCS of contralesional M1 may lead to further clinical deterioration (Bradnam et al., 2012). In this case, reducing perilesional activity could be a better strategy (Wu et al., 2013). Another factor involved in the outcome of tDCS therapy appears to be the level of residual GABA activity in the ipsilesional hemisphere. Actually, a greater motor improvement results from anodal tDCS of ipsilesional M1 in patients exhibiting higher GABA activity in the ipsilesional cortex (O’Shea et al., 2014). A bimodal balance-recovery model, linking interhemi-

spheric competition and functional recovery to the structural “neuronal reserve” spared by the lesion, was recently proposed to enable NIBS protocols to be tailored to the needs of individual patients (Di Pino et al., 2014).

To conclude, the possibility of promoting motor stroke recovery by tDCS still needs to be demonstrated in large, multicentric RCTs consisting of repeated sessions with prolonged follow-up. According to the currently published data, we can identify only some trends in predicting tDCS efficacy. The combination of tDCS with other therapies (e.g., virtual reality training (VRT) (Lee and Chun, 2014; Viana et al., 2014), occupational therapy (Nair et al., 2011; Zheng and Schlaug, 2015), robot-assisted training (Ochi et al., 2013; Picelli et al., 2015), or constraint-induced movement therapy (Bolognini et al., 2011; Cunningham et al., 2015; Rocha et al., 2016)) could result in synergistic effects to bring the effect of tDCS at a clinically meaningful level. This point is of particular importance and one of the main challenges in daily practice will be to optimize the combined approach of tDCS and rehabilitation therapies to produce maximum synergy in both directions, i.e. increasing the efficacy of tDCS through the action of rehabilitation therapies and vice versa.

In the future, experimental designs should also take into account the influence of stimulation parameters (site, intensity, duration), the phase of stroke (acute, post-acute, chronic), the degree of clinical impairment, and more importantly, the location and extent of stroke lesion. A proper selection of patients is needed, substantiated by a careful assessment of various anatomic-functional parameters at baseline, to avoid a negative impact of unsuccessful trials on the development of cortical stimulation strategies for treating stroke. As examples of failure, there are trials that included patients with severe cortical stroke unable to respond to such treatment (e.g., Hesse et al., 2011 for tDCS) or protocols that did not take into account stroke-induced plasticity to design stimulation location and settings (e.g., Harvey et al., 2009 for the EVEREST trial of implanted epidural cortical stimulation). Thus, the plastic changes in motor cortical representation and the integrity of the corticospinal tract should be carefully investigated by means of motor cortical mapping using navigated TMS (Ahdab et al., 2014; Mellerio et al., 2014) and functional neuroimaging techniques, such as diffusion tensor imaging tractography or analyses of resting-state or task-dependent motor network connectivity.

There are potentially other interesting indications of tDCS in the context of stroke, such as swallowing dysfunction (Kumar et al., 2011; Yang et al., 2012; Shigematsu et al., 2013) or spasticity (Hesse et al., 2011; Ochi et al., 2013; Vandermeeren et al., 2013; Wu et al., 2013; Lee and Chun, 2014; Viana et al., 2014). The issue of dysphagia was not further addressed in this work, since only one study including more than 10 patients receiving the active treatment has been reported so far (Shigematsu et al., 2013). Regarding spasticity, tDCS was mostly combined with other therapeutic strategies (VRT, physical therapy, robot-assisted training) as mentioned above. There were three large-scale sham-controlled studies: two are presented in Table 3 (Hesse et al., 2011; Viana et al., 2014) and one was a non-replicated study of cathodal tDCS of the contralesional motor cortex in patients in the chronic stroke phase (Wu et al., 2013). Reviews and meta-analyses can be found elsewhere on tDCS and dysphagia (Doeltgen et al., 2015; Yang et al., 2015; Pisegna et al., 2016) or spasticity (Elsner et al., 2016a).

Beyond motor impairment, stroke may also affect other neurological functions, such as speech and language production or awareness of the contralesional body or environment. A deficit in the first of these functions refers to aphasia, which will be discussed in the next chapter, whereas a deficit in the second of these functions refers to hemispatial neglect. A PubMed research (keywords: tDCS AND neglect AND stroke) identified 17 papers, including 6 original clinical trials and 41 patients. These studies

included only one to ten patients, with a certain methodological heterogeneity, therefore precluding any recommendation in this clinical condition.

7. Aphasia

Aphasia is a highly disabling language disorder frequently caused by a left-lateralized hemispheric stroke (Laska et al., 2001). Even if traditional linguistic-based therapies have been proved to induce an adequate clinical improvement (Basso et al., 2011; Code and Petheram, 2011; Brady et al., 2012), a large percentage of patients are left with some degree of language impairment (Lazar et al., 2010). It has been suggested that one of the key predictors for positive language outcomes is treatment intensity (i.e., more than 5 h of speech therapy per week) (Bhogal et al., 2003). Therefore, effective treatment approaches that might be used as an adjunct to common speech and language therapies are urgently needed to maximize the recovery process in aphasic patients. The recent application of NIBS techniques to language rehabilitation, such as tDCS, has already provided positive results (Monti et al., 2013). Generally, interhemispheric competition between the residual language areas in the damaged left hemisphere and the intact right hemisphere underlies the basic concept for tDCS language treatment (Kiran, 2012). In particular, it has been proposed that in patients with left hemispheric damage, the homotopic contralateral right hemispheric areas may be in a state of abnormally high activation and may exert an inhibitory effect over the stroke-affected hemisphere (Belin et al., 1996; Murase et al., 2004). Thus, a language improvement may be possible either by increasing the output of the perilesional left hemisphere through excitatory (anodal) tDCS, by decreasing the inhibition from the intact right hemisphere by applying inhibitory (cathodal) tDCS over the contralesional cortex, or both.

A PubMed search (keywords: tDCS AND aphasia) identified 102 papers, including 35 original clinical studies and 431 patients. Studies mainly concerned patients with nonfluent poststroke aphasia, while there are three studies on primary progressive aphasia (Wang et al., 2013; Cotelli et al., 2014b; Tsapkini et al., 2014), which will be not analyzed further, because of the low volume of reported data and the methodological heterogeneity of those studies. Regarding nonfluent poststroke aphasia, most studies were single case reports or small series of patients, including less than 10 patients receiving active stimulation, or based on single tDCS sessions (Class III or IV studies). Therefore, only 5 studies were retained for analysis regarding tDCS effects on nonfluent aphasics (Table 4). Anodal tDCS was applied over the Broca's area (left inferior frontal gyrus) in four studies and over the Wernicke's area (left postero-superior temporal gyrus) in two studies. However, we have to mention that the first tDCS work on aphasia showed that only cathodal tDCS (and not anodal tDCS) over a left frontotemporal region significantly improved the accuracy of the picture naming task in 8 chronic non-fluent post-stroke aphasic patients (Monti et al., 2008).

Regarding anodal tDCS applied over Broca's area, several sham-controlled studies issued from the same group (Fiori et al., 2013; Marangolo et al., 2013a,c, 2014a; Campana et al., 2015) and performed in series of 7–20 patients with nonfluent poststroke aphasia were in favour of a significant improvement of speech and language performance at the end of a protocol of 5–10 sessions of active tDCS. Conversely, two sham-controlled studies from another group (Polanowska et al., 2013a,b) did not find significant difference between active and sham conditions in language recovery after 15 sessions of tDCS performed in 24 nonfluent aphasics. These two sets of studies present several differences, including the post-stroke phase in which patients were included: either the

postacute phase (2 months in average) (Polanowska et al., 2013a,b) or the chronic phase (ranging from 6 months to 7 years) (Fiori et al., 2013; Marangolo et al., 2013a,c; Campana et al., 2015). Anyway, no recommendation can be drawn from these results.

There are several other studies based on single sessions or smaller sample size with the same tDCS montage. In the study published by Volpato et al. (2013), 2 nonfluent and 6 fluent aphasics at chronic stage (6–126 months after stroke) did not benefit from 10 sessions of anodal tDCS over Broca's area in object and action naming accuracy. In this latter study, tDCS was applied as a "single" therapy. In contrast, various studies showed the potential value of coupling multiple sessions of anodal tDCS over Broca's area with concurrent language or conversational therapy (Baker et al., 2010; Marangolo et al., 2011, 2013a,c, 2014a; Fiori et al., 2013; Campana et al., 2015). Except the study by Baker et al. (2010), all other studies were issued from the same group, showing significant tDCS-induced changes not only in naming performance but also in the recovery from articulatory disturbances and speech production deficits. In the study of Baker et al. (2010), 4 nonfluent and 6 fluent aphasics at a chronic stage (10–242 months after stroke) received 5 sessions of anodal tDCS over the left frontal cortex while performing a computerized anomia treatment. In this study, fMRI investigation was performed during an overt naming task in each individual to position the active anode over structurally intact frontal cortex. The tDCS protocol improved naming accuracy at least during one-week follow-up. One of the two non-fluent aphasics who received stimulation specifically over the Broca's area benefited from the treatment.

Regarding anodal tDCS applied over Wernicke's area, three studies found beneficial results of a protocol of 5 sessions of tDCS coupled with naming treatment in 12 patients with various types of aphasia in the postacute phase (3–6 months after stroke) (Wu et al., 2015) and in smaller groups of 3 nonfluent (Fiori et al., 2011) and 8 fluent (Fridriksson et al., 2011) aphasics at the chronic phase, with the improvement lasting up to 3 weeks after the end of the intervention. In contrast, this montage did not provide any significant improvement in auditory comprehension and naming in a series of 7 patients with various types of aphasia in the postacute phase (about one month after stroke) (You et al., 2011). Again, these results preclude any recommendation for anodal tDCS over the left hemisphere.

However, according to the concept of interhemispheric rivalry as the origin of poststroke functional changes, other tDCS studies aimed at stimulating cathodally the homologous regions of Broca's and Wernicke's areas in the right hemisphere.

Cathodal tDCS of the right homologous of Broca's area was performed in four studies (Jung et al., 2011; Kang et al., 2011; Vines et al., 2011; Cipollari et al., 2015), based on multiple session (3–10) protocols in patients at either postacute or chronic stage. Two of these studies showed improvement in verbal fluency but included only 6 nonfluent aphasics (Vines et al., 2011; Cipollari et al., 2015), while the other two studies were performed on respectively 10 (Kang et al., 2011) and 37 patients (Jung et al., 2011), the latter study being based on an open-label protocol. In the study by Kang et al. (2011), each patient received a daily session of cathodal tDCS for 5 consecutive days in a randomized cross-over manner coupled with conventional word-retrieval training. Significantly improved picture naming was observed at 1 h following the last active tDCS session but no changes were observed after sham tDCS. Some improvement was also reported after cathodal tDCS of the right homologous of Wernicke's area in a single case (Cherney et al., 2013) and in a series of 7 patients with various types of aphasia in the postacute phase (You et al., 2011). In contrast, this montage did not provide any significant improvement in 12 chronic aphasics (Flöel et al., 2011). Therefore, these results do not allow any recommendation to be proposed.

Another approach was to combine both anodal tDCS of the left inferior frontal gyrus and cathodal tDCS of the right inferior frontal gyrus in a bihemispheric ("dual") tDCS strategy. The first proof-of-concept was provided by an open-labelled single-session study performed in 6 nonfluent and 5 fluent aphasics at a chronic stage (Lee et al., 2013). Marangolo et al. (2013b, 2014b, 2016) and Cipollari et al. (2015) extended this result in a series of 6–9 nonfluent aphasics at a chronic stage receiving 10–15 sessions of bihemispheric tDCS combined with speech and language therapy. Improvement in picture description, noun and verb naming, word reading and repetition accuracy, and response time lasted up to one week after the intervention. However, these results still remain to be reproduced on a larger sample size by another independent team. It is interesting to note that a similar strategy of bihemispheric ("dual") stimulation was successfully applied using high-frequency rTMS over Broca's area combined with low-frequency rTMS over its right homologous to promote poststroke rehabilitation of aphasia (Khedr et al., 2014a).

We also have to mention that a bihemispheric tDCS strategy targeted on the DLPFC (and not the inferior frontal gyrus) was successfully applied in two open-labelled case series of 1–4 patients with chronic nonfluent aphasia (Manenti et al., 2015; Valiengo et al., 2016). Finally, one group chose the original strategy of stimulating the motor cortex combined with computer-assisted language therapy to improve recovery outcome in poststroke aphasia (Meinzer et al., 2016). In a recently reported trial including 26 patients with various types of poststroke aphasia, anodal tDCS administered for 2 weeks over the left M1 (C3 site, with the cathode over the right supraorbital region) was found to produce a beneficial effect on naming ability. Improvement after active vs. sham procedure was especially larger for trained items during follow-up (6 months after stimulation) and regarding transfer to untrained items (Meinzer et al., 2016). However, the value of this approach remains to be replicated by another research group.

To conclude, some beneficial results were reported using anodal tDCS over Broca's and Wernicke's areas, cathodal tDCS over the right homologue of Broca's area, or a bihemispheric stimulation of both inferior frontal gyri. However, the level of evidence is not sufficient to ensure the efficacy or the therapeutic potential of any of these protocols in the rehabilitation of poststroke aphasics. A similar conclusion was reported in a meta-analysis issued in 2013 and updated in 2015 (Elsner et al., 2013a, 2015). Moreover, direct comparisons between these different montages and approaches are lacking. Therefore, further studies are needed to identify which parameters of stimulation (e.g., anodal or cathodal monohemispheric or bihemispheric stimulation, stimulation intensity, session duration, interval between sessions...) can maximize tDCS effect on the recovery process. Most studies are case reports or have small sample size and some of them did not monitor the benefits obtained over time during and beyond the period of stimulation. Large, multicentric RCTs are needed to replicate the results and to assess different outcome measures, such as standardized tests of everyday communication abilities. If promoting effects of tDCS on stroke recovery are confirmed in larger samples of aphasic patients, the parameters of stimulation to use in daily practice should be clearly determined, as well as the optimal time after stroke to initiate the treatment, the type of aphasia to manage (nonfluent, fluent, or both) and the concomitant speech and language therapy to perform.

8. Multiple sclerosis

Multiple sclerosis (MS) is one of the most common neurological diseases and a serious cause of disability in young adults. Its natural course is characterized by recurrent relapses or progressive

Table 4
Repeated tDCS session protocols in poststroke nonfluent aphasics.

Articles	Number and type of patients (protocol design)	Stimulation electrode location	Stimulation intensity, session duration, total number of sessions (protocol duration; follow-up)	Clinical results	Class
<i>Anodal stimulation of Broca's area</i>					
Marangolo et al. (2013a)	12 nonfluent aphasics (chronic stroke: 7–84 months after stroke) (crossover; combined with conversational therapy)	Anode: left inferior frontal gyrus/Broca's area (F5). Cathode: right supraorbital region	1 mA, 20 min, 10 sessions (2 weeks, FU: 1 month)	Improvement in content units, verbs and sentences production after active vs. sham tDCS at the end of the intervention and 1 month later	II
Polanowska et al. (2013a)	24 nonfluent aphasics (postacute stroke: 2–24 weeks after stroke) (14 active, 10 sham; combined with speech and language therapy)	Anode: left inferior frontal gyrus/Broca's area (between T3-Fz and F7-Cz). Cathode: right supraorbital region	1 mA, 10 min, 15 sessions (3 weeks, FU: 3 months)	No difference in naming accuracy and time after active vs. sham tDCS at the end of the intervention and 3 months later, but higher effect sizes in naming time after active tDCS	III
Polanowska et al. (2013b)	24 nonfluent and 13 fluent aphasics (postacute stroke: 2–24 weeks after stroke) (18 active, 19 sham; combined with speech and language therapy)	Anode: left inferior frontal gyrus/Broca's area (between T3-Fz and F7-Cz). Cathode: right supraorbital region	1 mA, 10 min, 15 sessions (3 weeks, FU: 3 months)	No difference in naming, comprehension, and verbal repetition after active vs. sham tDCS at the end of the intervention and 3 months later, but higher effect sizes in naming and verbal repetition after active tDCS	III
Campana et al. (2015)	20 nonfluent aphasics (chronic stroke: 6–84 months after stroke) (crossover; combined with conversational therapy)	Anode: left inferior frontal gyrus/Broca's area (F5). Cathode: right supraorbital region	2 mA, 20 min, 10 sessions (2 weeks, no FU)	Improvement in picture description, noun and verb naming after active tDCS at the end of the intervention, with difference according to the integrity of different left subcortical structures	II

No recommendation for anodal tDCS of left Broca's area in nonfluent poststroke aphasics.
EEG: electroencephalography; FU: follow-up.

functional decline. With disease evolution, patients could accumulate several neurological dysfunctions or disease-related complications including motor deficit, fatigue, tremor, spasticity, sensory disturbances, pain, genital or urinary symptoms, and psychiatric or cognitive disorders. Many of these clinical aspects are difficult to manage, being resistant to pharmacological treatments. Thus, dealing with MS complications constitutes a real challenge to every person in charge, making new approaches much needed in this domain. The effects of tDCS have been assessed on various symptoms in MS patients. A PubMed search (keywords: tDCS AND multiple sclerosis) identified 19 papers, including 11 original clinical studies and 205 patients. The topic of these 11 studies was as follows:

- fatigue (Ferrucci et al., 2014; Saiote et al., 2014; Tecchio et al., 2014, 2015; Ayache et al., 2016);
- cognition, attention and executive function (Ayache et al., 2016; Mattioli et al., 2016);
- motor performance (Cuyper et al., 2013; Meesen et al., 2014);
- spasticity (Iodice et al., 2015);
- pain or tactile sensory deficit (Mori et al., 2010, 2013; Ayache et al., 2016).

To date, the main MS domain investigated in tDCS trials concerned fatigue, a very frequent symptom in MS patients, with a complex pathophysiology, mixing pathological changes related to the disease itself and various comorbidities which may be accessible to NIBS techniques (Palm et al., 2014a; Chalah et al., 2015). Protocols varied greatly between studies, including the cortical target, which was either the bilateral motor cortex (Ferrucci et al., 2014), the bilateral sensory or sensory-motor cortex (Tecchio et al., 2014, 2015), or the left DLPFC (Saiote et al., 2014; Ayache et al., 2016). Data provided by motor or sensory cortex tDCS are summarized in Table 5, showing a mean reduction of 28% of the score on the modified fatigue impact scale (mFIS) after active tDCS, whatever the montage and the study. However, given the methodological heterogeneity of the two types of study (Ferrucci et al., 2014 vs. Tecchio et al., 2014, 2015), no recommendation can be made.

Regarding anodal tDCS of the left DLPFC (F3), no significant effect was observed after either 3 daily sessions performed in 8 patients with relapsing-remitting (RR) or progressive MS (Ayache et al., 2016) or 5 daily sessions performed in 13 patients with RR-MS (Saiote et al., 2014). However, in the latter study, the responders to tDCS were characterized by a higher prefrontal lesion load in brain MRI analysis, which might favour tDCS targeting over the lesioned areas in MS.

Regarding cognition and executive function, Mattioli et al. (2016) reported in 20 MS patients (10 in the active arm and 10 in the sham arm) that 10 daily sessions of anodal tDCS of the left DLPFC could improve the impact of cognitive training (performed concurrently with tDCS) on attention and speed of information processing. The effects were found to persist up to 6 months after the intervention. These effects on attention were not replicated in another study of 16 MS patients (8 in the active arm and 8 in the sham arm) (Ayache et al., 2016).

Regarding motor performance, Cuyper et al. (2013) showed that a single session of anodal tDCS of M1, contralateral to the most impaired hand, increased motor corticospinal output and strength in MS patients. Therefore, the authors suggested that tDCS could be considered in motor training protocols for the rehabilitation of MS patients. However, Meesen et al. (2014) tested the add-on value of a single session of anodal tDCS of M1, contralateral to the most impaired hand, on motor training in MS patients. They did not find any difference between active and sham conditions, especially regarding finger tapping test. These single-session results should be interpreted with caution, since multiple sessions are probably required to bring tDCS effects to a clinically meaningful level.

Regarding spasticity, Iodice et al. (2015) showed in a sham-controlled parallel-arm study of 20 RR-MS patients that a 5-day protocol of anodal tDCS delivered to M1 of the most affected side produced no significant impact on the modified Ashworth scale (MAS) or other scales relative to MS spasticity or walking abilities.

Finally, three studies with a parallel-arm design investigated the effect of tDCS on sensory aspects of MS. The first study consisted of 5 sessions of anodal tDCS applied over the motor cortex (C3/C4 in the 10–20 system of EEG electrode placement) contralat-

Table 5
Repeated tDCS session protocols in multiple sclerosis fatigue.

Articles	Number and type of patients (protocol design)	Stimulation electrode location	Stimulation intensity, session duration, total number of sessions (protocol duration; follow-up)	Clinical results	Class
Ferrucci et al. (2014)	23 patients (19 RR, 4 SP; EDSS 0–6.5) (crossover)	Anode: bilateral motor cortex (C3 + C4). Cathode: right deltoid muscle	1.5 mA, 15 min, 5 sessions (1 week; FU: 3 weeks)	Fatigue reduction (mean (mFIS): –28%) after active but not sham tDCS at the end of the intervention. After active tDCS, 15/23 patients (65%) were considered responders up to 3 weeks after	II
Tecchio et al. (2014)	10 patients (7 RR, 1 SP, 2 PP; EDSS 0–3.5) (crossover)	Anode: whole body S1 personalized electrode. Cathode: Occipital (Oz)	1.5 mA, 15 min, 5 sessions (1 week; FU: 8 weeks)	Fatigue reduction (mean (mFIS): –28%) after active but not sham tDCS at the end of the intervention	II
Tecchio et al. (2015)	13 patients (13 RR; EDSS 0–3.5) (crossover)	Anode: whole body S1 personalized electrode. Cathode: Occipital (Oz)	1.5 mA, 15 min, 5 sessions (1 week; no FU)	Fatigue reduction (mean (mFIS): –28%) after active but not sham tDCS at the end of the intervention, without correlation with MEP and SEP changes	II

No recommendation for anodal tDCS of sensory or motor cortex in multiple sclerosis fatigue.

EDSS: Expanded Disability Status Scale; FU: follow-up; MEP: motor evoked potentials; mFIS: modified fatigue impact scale; PP: primary progressive; RR: relapsing–remitting; S1: primary somatosensory cortex; SEP: somatosensory evoked potentials; SP: secondary progressive.

eral to the painful somatic area in 19 RR-MS patients (10 in the active arm and 9 in the sham arm) (Mori et al., 2010). A significant pain relief was observed after active tDCS compared to sham tDCS, while there was no change in depression or anxiety scores. In the second study, the same authors performed 5 sessions of anodal tDCS 2 cm posteriorly to the C3/C4 position in order to stimulate S1, contralateral to the hypoesthetic upper limb of 20 RR-MS patients (10 in the active arm and 10 in the sham arm) (Mori et al., 2013). They found a significant improvement of tactile discriminatory thresholds and sensation scores after anodal tDCS compared to sham stimulation, again without any impact on depression scores (Mori et al., 2013). Finally, in a third study including 16 MS patients (8 in the active arm and 8 in the sham arm), three consecutive daily sessions of anodal tDCS applied to the left DLPFC were found to produce significant analgesic effects compared to a sham condition, without concomitant improvement on mood, fatigue, or attention (Ayache et al., 2016).

In summary, tDCS studies in the MS domain are sparse and results are still preliminary and heterogenous regarding the methods used and the symptoms to treat. Therefore, no recommendations can be made.

9. Epilepsy

Although NIBS techniques aimed at modifying cortical excitability, the study of their therapeutic potential in epilepsy remains underdeveloped. This is the case for rTMS (Lefaucheur et al., 2014) and even more for tDCS. Actually, a PubMed search (keywords: tDCS AND Epilepsy) identified 65 papers, including only 10 original clinical studies and 147 patients. Moreover, 5 of these studies were case reports of 1–5 patients, while 5 sham-controlled studies with crossover or parallel-arm design included 12–37 patients (Fregni et al., 2006g; Auvichayapat et al., 2013; Liu et al., 2016; San-Juan et al., 2016; Tekturk et al., 2016b). Two of these studies were based on a single tDCS session (Fregni et al., 2006g; Auvichayapat et al., 2013), while another study (Liu et al., 2016) explored the safety and antidepressant efficacy of a multiple (5-day) tDCS session protocol in a series of epileptic patients, but did not address the question of the antiepileptic potential of tDCS.

In Fregni et al. (2006g), tDCS was targeted over the epileptogenic focus in 19 patients with focal epilepsy due to cortical dysplasia. A single session of active cathodal tDCS delivered at 1 mA for 20 min and performed in 10 of these patients, led to a reduction in epileptic discharge frequency, with a trend towards a decrease in the number

of clinical seizures. The remaining 9 patients did not benefit from sham tDCS. In Auvichayapat et al. (2013), cathodal tDCS was also applied at 1 mA as a single session of 20 min over the seizure focus in a series of 29 children with focal epilepsy (29 patients in the active tDCS group and 7 patients in the sham tDCS group). A reduction in epileptic discharge frequency was observed up to 48 h after active tDCS, but the final result was clinically negligible.

In Liu et al. (2016), anodal tDCS (2 mA) was applied for 20 min over the left DLPFC (F3), with the cathode over the right supraorbital area, for 5 consecutive days, according to a depression therapy protocol. Thirty-three patients with temporal lobe epilepsy completed the study (21 patients in the active tDCS group and 12 patients in the sham tDCS group). Beyond the antidepressant effects, active tDCS did not increase seizure or interictal discharge frequency. This study provides evidence for the safety of anodal tDCS of left DLPFC in epileptic patients, but was not intended to investigate antiepileptic therapy.

Few case reports or small sample studies have shown the value of repeated cathodal tDCS sessions applied over the epileptic focus to reduce epileptic EEG activity or the number of seizures, e.g. 4–5 tDCS sessions in 2–5 patients with Rasmussen's encephalitis (San-Juan et al., 2011; Tekturk et al., 2016a) and 2 tDCS sessions in 2 patients with focal epilepsy (Assenza et al., 2014). The effect of repeated cathodal tDCS sessions on seizure frequency was recently reported in larger populations of patients with mesial temporal lobe epilepsy and hippocampal sclerosis (San-Juan et al., 2016; Tekturk et al., 2016b). In the first study of 28 patients with a parallel-arm design (20 patients in the active arm and only 8 patients in the sham arm) (San-Juan et al., 2016), the cathode was positioned over the most active area of interictal epileptiform discharges defined on scalp EEG. In the second study of 12 patients with a crossover design (Tekturk et al., 2016b), the cathode was placed over the temporal region (T3 or T4), contralateral to the most affected side. In both studies, the anode was placed over the contralateral supraorbital region and tDCS was delivered at 2 mA for 30 min in 3–5 sessions performed on consecutive days. The mean seizure frequency significantly decreased after active but not sham tDCS in both studies, even associated with a reduction of interictal epileptiform discharges on scalp EEG immediately after tDCS (San-Juan et al., 2016). However, the comparability of the procedure used in these two studies remains to be determined, especially regarding cathode location and therefore, no recommendation can be made about the potential efficacy of tDCS in the treatment of any type of epilepsy.

10. Disorders of consciousness

Disorders of consciousness, such as minimally conscious state (MCS) and vegetative state (VS), are highly challenging clinical conditions for treatment. A PubMed search (keywords: tDCS AND vegetative state OR disorders of consciousness) identified 23 papers, including 4 original clinical studies and 79 patients. These four studies included 10, 30, 25, and 14 patients, respectively (Angelakis et al., 2014; Thibaut et al., 2014; Naro et al., 2015, 2016). The left DLPFC was targeted with anodal tDCS applied for 20 min at 2 mA and for 5 days in a first study based on a limited number of patients (3 patients in MCS and 7 patients in VS) (Angelakis et al., 2014) and only as a single session for the second study, which included a larger sample size (30 patients in MCS and 25 patients in VS) (Thibaut et al., 2014). Both studies, from independent groups, arrived at a similar conclusion: patients with MCS but not those with persistent VS or coma can benefit from anodal tDCS of the left DLPFC, combined with cathodal tDCS of the right homologue area (Thibaut et al., 2014) or the right orbitofrontal cortex (Angelakis et al., 2014).

Another group delivered single sessions of anodal tDCS over the orbitofrontal cortex, the DLPFC, or a parieto-occipital region in 25 and 14 patients affected by various disorders of consciousness (Naro et al., 2015, 2016). More particularly, these authors intended to show that the response to tDCS could demonstrate the persistence of residual functional connectivity within large-scale brain networks in patients with MCS or more severe disorders of consciousness.

In conclusion, some beneficial results of tDCS protocols have been shown in patients with disorders of consciousness, especially targeting the left DLPFC in MCS. However, the reported data are very preliminary, obtained in small samples, with heterogeneous outcome measures, including either clinical or functional connectivity variables. Therefore, no recommendation can be made, especially regarding the number of sessions and the amount and clinical profile of the patients to treat.

11. Alzheimer's disease

Since its updating in the early 2000s, tDCS has been widely used in neuropsychological studies to act on cognitive and behavioural features, e.g., attention, memory and working memory, computation, decision-making, and so on, in either healthy humans or patients with various neuropsychiatric diseases (Shin et al., 2015; Hill et al., 2016). Therefore, there are a lot of expectations regarding the therapeutic potential of tDCS to modulate psychological processes in cognitive disorders, such as Alzheimer's disease (AD). A PubMed search (keywords: tDCS AND Alzheimer's disease) identified 46 papers, including 9 original clinical studies and 189 patients. Among these 9 studies, there are 1 case report, 1 study on patients with mild cognitive impairment (MCI), and 7 studies that included 10–40 AD patients (Ferrucci et al., 2008a; Boggio et al., 2009a, 2012; Cotelli et al., 2014a; Khedr et al., 2014b; Suemoto et al., 2014; Bystad et al., 2016).

The main target explored was the left DLPFC, which was intended to be activated by anodal tDCS to improve cognitive performance. In this domain, the four published studies showed different primary outcome assessments that were a visual recognition memory task (Boggio et al., 2009a), a face-name association task (Cotelli et al., 2014a), an apathy score (Suemoto et al., 2014), or the Mini Mental State Examination (MMSE) (Khedr et al., 2014b). The initial single-session study showed memory improvement in 10 patients having received active anodal tDCS of the left DLPFC (Boggio et al., 2009a). Three more recent sham-controlled studies were retained for analysis (Table 6), including 11–20 AD

patients having received the active condition in a protocol comprising several tDCS sessions. No safety problems emerged in these studies, in which the left DLPFC was targeted with anodal tDCS applied for 20–25 min at 2 mA for 6–10 sessions performed within two weeks. One study also considered cathodal stimulation of the left DLPFC (Khedr et al., 2014b), while another study explored the value of tDCS combined with memory training (Cotelli et al., 2014a). Although one study showed a significant cognitive improvement on MMSE after both anodal and cathodal tDCS of the left DLPFC, lasting for up to 2 months after the intervention (Khedr et al., 2014b), the other two studies were negative. One study showed that active tDCS had no additional value compared to sham tDCS on the improvement in cognitive performance provided by memory training (Cotelli et al., 2014a). The other study, the largest sham-controlled RCT published to date in this domain (Suemoto et al., 2014), which was adequately powered for disclosing minimally clinically significant differences after the intervention, did not show any significant effect of the active anodal tDCS condition targeting the left DLPFC. Therefore, no recommendation can be currently made regarding the efficacy of anodal tDCS of the left DLPFC to improve cognitive performance in AD patients.

Besides the left DLPFC, the other studies aimed at targeting a temporo-parietal region bilaterally with anodal tDCS, placing one anode over each hemisphere and a cathode at an extracranial location (deltoid muscle). The stimulation was applied for 15–30 min at 2 mA during repeated daily sessions for 5 days in one study (Boggio et al., 2012) but only in a single session in two other studies that included 10 AD patients each (Ferrucci et al., 2008a; Boggio et al., 2009a). The primary aim was to improve recognition memory. The initial single-session studies showed beneficial effect on word or visual recognition memory, but this result was not confirmed by a subsequent multiple-session RCT (Boggio et al., 2012). In this latter crossover study, including 15 AD patients, visual recognition memory was improved after active vs. sham anodal tDCS of the both temporal cortices at one month after the intervention, but the statistical interaction “time x group” was not significant. Therefore, no recommendation can be currently made regarding the efficacy of bilateral anodal tDCS of the temporo-parietal cortex to improve cognitive performance in AD patients.

12. Tinnitus

Tinnitus is a phantom perception of a sound in the absence of a corresponding external sound source and occurs in 5–15% of the population (Axelsson and Ringdahl, 1989; Heller, 2003; Gallus et al., 2015). Whereas many patients can habituate to this sound, quality of life is severely disrupted in about 25% of the patients who cannot cope with the tinnitus (Axelsson and Ringdahl, 1989). In these patients, tinnitus is frequently associated with anxiety, depression, cognitive impairment, and sleep disturbances.

Although numerous treatments have been introduced, evidence for an uniformly successful treatment is lacking (Langguth et al., 2013). The lack of efficient therapies for tinnitus partly originates from the heterogeneity of tinnitus and an incomplete understanding of the pathophysiology of the different forms of tinnitus (Elgoyhen et al., 2015). In most cases, tinnitus is triggered by hearing loss or abnormalities in the inner ear or the peripheral auditory pathway. This results in neuroplastic changes in the central nervous system encompassing a wide network of auditory and non-auditory brain areas (De Ridder et al., 2014). However, some forms of tinnitus appear to be unrelated to hearing loss, which probably reflect a different pathophysiological mechanism and require therefore perhaps a different strategy of neuromodulation (Vanneste and De Ridder, 2015).

Over the last decade, tDCS has been used for elucidating the involvement of specific brain networks in tinnitus pathophysiology

Table 6
Repeated tDCS session protocols in Alzheimer's disease.

Articles	Number and type of patients (protocol design)	Stimulation electrode location	Stimulation intensity, session duration, total number of sessions (protocol duration; follow-up)	Clinical results	Class
Cotelli et al. (2014a)	36 patients (mean MMSE 20–22) (12 active + memory training, 12 active + motor training, 12 sham + memory training)	Anode: left DLPFC. Cathode: right deltoid muscle	2 mA, 25 min, 10 sessions (2 weeks; FU: 6 months)	No difference in cognitive performance improvement (face-name association task) after active vs. sham tDCS combined with memory training, but no improvement when combined with motor training	II
Khedr et al. (2014b)	34 patients (MMSE 12–23) (11 anodal, 12 cathodal, 11 sham)	Anode: left DLPFC. Cathode: right supraorbital region (or the reverse)	2 mA, 25 min, 10 sessions (2 weeks; FU: 2 months)	Improvement in cognitive performance (MMSE) after either anodal or cathodal vs. sham tDCS at 2 months after the intervention, with reduction of P300 latency, but no effect on M1 excitability	II
Suemoto et al. (2014)	40 patients (MMSE 10–20) (20 active, 20 sham)	Anode: left DLPFC. Cathode: right supraorbital region	2 mA, 20 min, 6 sessions (2 weeks; FU: 1 week)	No change in apathy scores, global cognition, and neuropsychiatric symptoms after active vs. sham tDCS	II
Bystad et al. (2016)	25 patients (MMSE > 17) (12 active, 13 sham)	Anode: left temporal lobe (T3). Cathode: right supraorbital region	2 mA, 30 min, 6 sessions (2 weeks; no FU)	No change in verbal memory function after active vs. sham tDCS	II

No recommendation for anodal tDCS of the left DLPFC in Alzheimer's disease.

DLPFC: dorsolateral prefrontal cortex; FU: follow-up; M1: primary motor cortex; MMSE: Mini Mental State Examination.

Table 7
Repeated tDCS session protocols in tinnitus.

Articles	Number and type of patients (protocol design)	Stimulation electrode location	Stimulation intensity, session duration, total number of sessions (protocol duration; follow-up)	Clinical results	Class
Shekhawat et al. (2013a)	40 patients (20 active, 20 sham; followed by sound therapy from hearing aid use for 6 months)	Anode: left temporo-parietal cortex (between C3 and T5). Cathode: right supraorbital region (F8)	2 mA, 20 min, 5 sessions (1 week; FU: 6 months)	No difference in the effect on tinnitus functional index, handicap questionnaire, and severity scores after active vs. sham tDCS	II
Teismann et al. (2014)	32 patients (10 anodal, 11 cathodal, 11 sham; combined with tailor-made notched music training)	Anode: left temporo-parietal cortex/Heschl's Gyrus (between C3 and T3, 1 cm inferior). Cathode: right supraorbital region	2 mA, 30 min, 5 sessions (1 week; FU: 31 days)	No difference in the effect on tinnitus handicap questionnaire and inventory after either anodal or cathodal vs. sham tDCS	II
Forogh et al. (2016)	22 patients (11 active, 11 sham)	Anode: left temporo-parietal cortex (between C3 and T5). Cathode: right supraorbital region	2 mA, 20 min, 5 sessions (1 week; FU: 2 weeks)	No difference in the effect on tinnitus handicap inventory and VAS after active vs. sham tDCS	II
Hyvärinen et al. (2016)	19 patients (10 active, 9 sham)	Anode: left temporal cortex. Cathode: right frontal region	2 mA, 20 min, 10 sessions (10 consecutive days; FU: 4 weeks after treatment start)	No difference in the effect on tinnitus handicap inventory after active vs. sham tDCS	II

Recommendation: anodal tDCS of the left temporo-parietal cortex is probably ineffective in chronic tinnitus (Level B).

FU: follow-up; VAS: visual analogue scale.

and has also been investigated as a novel therapeutic approach for tinnitus patients (Langguth et al., 2013). A PubMed search (keywords: tDCS AND tinnitus) identified 48 papers, including 23 original clinical studies and 2,335 patients, but the included patients were largely redundant among studies. In addition, most of these studies have investigated the immediate or short-term effect of single tDCS sessions on tinnitus perception. Longer lasting effects of multiple tDCS sessions were only assessed in 9 studies involving 172 patients treated with active tDCS. Finally, a variety of tDCS montages have been evaluated, targeting either the auditory cortex or the DLPFC or both.

From literature data, only 4 original sham-controlled studies including at least 10 patients who received active tDCS for multiple sessions were retained for analysis (Table 7). All these studies concerned anodal tDCS of the left temporal or temporoparietal (auditory) cortex. Neuroimaging has demonstrated abnormalities

of oscillatory brain activity, connectivity and metabolism in the auditory cortex of tinnitus patients (De Ridder et al., 2014). These changes in the auditory cortical area led to the hypothesis that it should be possible to treat tinnitus by modulating these abnormalities through the stimulation of the brain. In an initial study, Fregni et al. (2006f) targeted the left temporal cortex in 7 patients with anodal tDCS (placing the cathodal electrode supraorbital) for a single session of 3 min with a 1 mA intensity. They demonstrated a significant tinnitus reduction of 42% in 3 out of 7 patients. In a double-blind placebo-controlled follow-up study including 20 patients, Garin et al. (2011) also found a significant effect of a single session of anodal tDCS of the left temporal cortex (1 mA for 20 min) in comparison to cathodal and sham stimulation on tinnitus loudness immediately and still one hour after stimulation. A further study investigating dose/effects revealed that single sessions of anodal tDCS of the left temporal cortex were more effective when

stimulation was performed at higher stimulation intensity (2 mA) for 20 min (Shekhawat et al., 2013b). Using these parameters, Joos et al. (2014) found in a large series of patients with tinnitus that a single session of anodal stimulation of the left temporal cortex (39 patients), but not of the right temporal cortex (136 patients) could lead to significant tinnitus reduction. Vanneste et al. (2013a) applied tDCS at 1.5 mA for 20 min bilaterally on the temporal cortices (T3 + T4) comparing the combination of left anode + right cathode (20 patients) versus right anode + left cathode (16 patients) and did not find any difference in the change provided by these two montages on tinnitus distress and loudness. In the same study, these authors also compared the effect of transcranial alternating current stimulation (tACS) and transcranial random noise stimulation (tRNS) applied bilaterally over the temporal cortices. A significant tinnitus reduction was observed after tRNS, but not after tDCS or tACS. Based on the hypothesis that neuroplastic changes can be promoted by tDCS, two recent studies have investigated the value of combining repeated sessions of anodal tDCS of the left temporal cortex with sound therapy (tailor-made notched music training) (Teismann et al., 2014) or hearing aids (Shekhawat et al., 2013a). However, both studies did not show any add-on effect of tDCS to the audiological treatment. Two recent studies (Forough et al., 2016; Hyvärinen et al., 2016) were also negative. Forough et al. (2016) reported the absence of efficacy of 5 sessions of active anodal tDCS of the left temporal cortex on tinnitus severity in 11 patients. In the study of Hyvärinen et al. (2016), two different montages were compared, either anodal tDCS of the left temporal cortex (10 patients) or a bifrontal montage with the anode on the left and the cathode on the right side (9 patients), while 11 patients received sham stimulation. These authors found no difference between active and sham groups in the effect of 10 sessions of tDCS on tinnitus severity, tDCS being applied on consecutive days as at-home treatment. Therefore, according to these replicated negative results, we can conclude that there is a level of evidence B in favour of the probable absence of efficacy of anodal tDCS of the left temporoparietal cortex to relieve chronic tinnitus.

Other studies were designed to target the DLPFC. The rationale of DLPFC stimulation for tinnitus relief was based on neuroimaging studies showing the involvement of frontal areas in tinnitus pathophysiology (Vanneste and De Ridder, 2011; Joos et al., 2012), as well as on studies reporting clinical benefits of tDCS of the DLPFC in the treatment of major depression, which is a frequent comorbid disorder in tinnitus (Langguth et al., 2011). In a first open-labelled exploratory study (Vanneste et al., 2010), single sessions of tDCS were delivered at 1.5 mA for 20 min with the cathode over the left DLPFC (F3) and the anode over the right DLPFC (F4) (438 patients). This tDCS protocol led to a 30% suppressive effect of the tinnitus percept. Conversely, the reverse montage (left anode and right cathode) was assessed in 30 patients, but did not produce any tinnitus-suppressing effect. Several retrospective or not-controlled single-session studies of the same group further confirmed the value of bihemispheric DLPFC stimulation with left cathode and right anode for providing some tinnitus relief (Vanneste et al., 2011, 2013a,b). One study showed that bihemispheric DLPFC stimulation using tDCS could modulate tinnitus annoyance and loudness, whereas alpha-modulated tACS does not yield a similar result (Vanneste et al., 2013b). An EEG study of functional brain connectivity (coherence and phase synchronization assessment) showed that the responders to bihemispheric DLPFC tDCS differed from non-responders according to their resting brain activity in the right auditory cortex and parahippocampal area and the functional connectivity between DLPFC and the subgenual anterior cingulate cortex in particular (Vanneste et al., 2011). In an open-label study including 32 patients receiving 6 sessions of bihemispheric DLPFC tDCS with the cathode over the left DLPFC and the anode over the right DLPFC (1.5 mA, 30 min, 2 ses-

sions per week), a small clinical effect on both tinnitus loudness and discomfort was also reported, particularly in women (Frank et al., 2012). However, in a randomized double-blind, sham-controlled study, Faber et al. (2012) found a beneficial effect on tinnitus annoyance (but not a reduction in tinnitus intensity) of anodal tDCS applied for six sessions either to the right DLPFC (7 patients) or to the left DLPFC (8 patients), with the cathode placed over the contralateral DLPFC. The effect of anodal tDCS of the DLPFC on tinnitus was irrespective of the laterality of the anode, whereas depression was preferentially modulated by left DLPFC anodal tDCS and anxiety by right DLPFC anodal tDCS. Thus, the results reported in the literature remain too preliminary to make a recommendation regarding the potential efficacy of any tDCS protocol targeted to the DLPFC for reducing either tinnitus discomfort or loudness in patients with chronic tinnitus.

Finally, we have to mention some studies using original montages, different from usually performed bipolar tDCS. First, an open-labelled study including 27 patients with chronic tinnitus (>2 years) (Shekhawat et al., 2016) showed that a single session of tDCS with multipolar Laplacian montage centered on either the temporal cortex or the DLPFC of the left hemisphere was equally effective for suppressing tinnitus loudness and annoyance, compared to classical bipolar montage, when the stimulation was applied at 2 mA for 20 min. Second, in a large parallel-arm sham-controlled study (Pal et al., 2015), 42 patients (21 in the active group and 21 in the sham group) received 5 daily sessions of tDCS (2 mA, 20 min, 1 week) with one large anode placed over the prefrontal cortices (F3-Fz-F4) and two smaller cathodes placed bilaterally over the temporal auditory cortical areas (T3 + T4). No difference in the effect of tDCS on tinnitus handicap inventory, severity scale, hospital anxiety and depression scale, and tinnitus intensity and distress was observed between the active and the sham groups from the end of the intervention up to 3 months later.

In summary, tDCS effects on tinnitus are not straightforward, depend on the methods and montages used, and have not been replicated by independent groups in large sham-controlled trials comprising multiple daily sessions. A further next step might be the evaluation of tRNS applied bilaterally over the auditory cortices, which was shown to be superior to tDCS in reducing tinnitus distress and loudness in one single-session study (Vanneste et al., 2013a). A recently published study of tRNS of the auditory cortices in 154 patients with non-pulsatile tinnitus showed differential effects of tRNS on various tinnitus features according to stimulation frequency (Joos et al., 2015). While either low-frequency (0.1–100 Hz) or high-frequency (100–640 Hz) tRNS produced beneficial effects, the combination of both frequencies was not able to improve tinnitus. Finally, the considerable variety of design options (tDCS, tACS and tRNS), electrode montages, stimulation parameters, or frequency range concerning tACS and tRNS, opens up an unlimited amount of neuromodulation possibilities that could create a chaotic wealth of data.

13. Depression

The rationale for the use of tDCS in the treatment of depressive disorders is based on the knowledge of functional and structural abnormalities in the left and right dorsolateral and ventromedial prefrontal cortex, amygdala and hippocampus in depressed patients (Campbell et al., 2004; Hamilton et al., 2008; Koenigs and Grafman, 2009). The aim of the NIBS techniques is to normalize the interhemispheric imbalance of neuronal activity between the both DLPFC areas, which was highlighted in this condition by, e.g., EEG analyses (Reid et al., 1998; Debener et al., 2000). The same rationale led to the development of rTMS therapy applied to the DLPFC, with a definite or probable evidence of antidepress-

sant efficacy, for high-frequency rTMS of the left DLPFC or low-frequency rTMS of the right DLPFC, respectively (Lefaucheur et al., 2014).

Regarding tDCS, the current approach is to enhance neural activity in the left DLPFC with anodal stimulation and/or to reduce neural activity in the right DLPFC with cathodal stimulation (Brunoni et al., 2012). Neuroimaging and computer modeling studies of tDCS suggest that in fact, tDCS also largely affects deeper brain structures, such as amygdala, hippocampus, and subgenual cortex (Keeser et al., 2011a,b; Bikson et al., 2012; Peña-Gómez et al., 2012). However, it is still unknown what changes in resting state brain networks are responsible for the antidepressant efficacy of tDCS. According to the various montages used, the respective impact of each electrode on brain network modulation also remains unclear.

A PubMed search (keywords: tDCS AND depression) identified 287 papers, including 39 original clinical studies and 988 patients, partially redundant (ancillary studies of the SELECT-tDCS trial for example). The Table 8 presents the results obtained in sham-controlled studies including at least 10 patients receiving repeated

daily sessions of active anodal tDCS of the left DLPFC, according to the two main montages, with the cathode over the right orbitofrontal cortex or the right DLPFC.

13.1. Antidepressant effects

The antidepressant effect of anodal tDCS of the left DLPFC was first described by Fregni et al. (2006b,c). Since then, more than 10 sham-controlled RCTs were published in this context (Fregni et al., 2006b,c; Boggio et al., 2007, 2008a; Rigonatti et al., 2008; Loo et al., 2010, 2012; Blumberger et al., 2012; Palm et al., 2012; Brunoni et al., 2013b), as well as various open-labelled studies and case reports. While RCTs investigated the therapeutic effects of tDCS in various patient samples (e.g., drug-resistant depression, unipolar versus bipolar depression) with different aims (add-on-treatment, comparison to pharmacotherapy, long-term treatment, comparison of different stimulation settings), the case reports are rather dealing with side-effects of tDCS (e.g., induction of hypomania).

Table 8
Repeated tDCS session protocols in depression.

Articles	Number and type of patients (protocol design)	Stimulation electrode location	Stimulation intensity, session duration, total number of sessions (protocol duration; follow-up)	Clinical results	Class
<i>Anodal tDCS of the left DLPFC with right orbitofrontal cathode</i>					
Boggio et al. (2008a)	40 patients (non-medicated MDD) (21 active DLPFC, 9 active occipital, 10 sham)	Anode: left DLPFC (F3) or occipital cortex (Oz). Cathode: right orbitofrontal region	2 mA, 20 min, 10 sessions (2 weeks; FU: 30 days)	Mood improvement (HDRS, BDI) after active vs. sham tDCS of the left DLPFC	II
Loo et al., 2010	34 patients (MDD, including 20 non-medicated, MADRS >20) (19 active, 15 sham)	Anode: left DLPFC (F3). Cathode: right orbitofrontal region	1 mA, 20 min, 5 active or sham sessions (1.5 week), followed by 5 active sessions (1.5 week; FU: 1 month)	No difference in mood improvement (HDRS-17, MADRS) after active vs. sham tDCS	II
Loo et al. (2012)	60 patients (MDD, including 17 non-medicated and 8 bipolars, MADRS >20) (31 active, 29 sham)	Anode: left DLPFC (F3). Cathode: right orbitofrontal region (F8)	2 mA, 20 min, 15 active or sham sessions (3 weeks), followed by 15 active sessions (3 weeks; FU: 1 month)	Mood improvement (MADRS) after active vs. sham tDCS, but no difference in responder rate (13%)	I
Palm et al. (2012)	22 patients (drug-resistant MDD, including 2 bipolars) (crossover)	Anode: left DLPFC (F3). Cathode: right orbitofrontal region	1–2 mA, 20 min, 10 sessions (2 weeks; no FU)	No difference in mood improvement (HDRS-24) after active vs. sham tDCS, but a better efficacy for the first study phase of the crossover trial and an increase in positive emotions after active tDCS	II
Bennabi et al. (2015)	23 patients (drug-resistant MDD, no bipolar, MADRS > 25) (12 active, 11 sham)	Anode: left DLPFC (F3). Cathode: right orbitofrontal region (FP2)	2 mA, 30 min, 10 sessions (1 week; FU: 30 days)	No difference in mood improvement (HDRS, MADRS), responder rate, or changes in neuropsychological tests after active vs. sham tDCS	II
Recommendation: anodal tDCS of the left DLPFC with right orbitofrontal cathode is probably effective in patients with no drug-resistant major depressive episode (Level B) and probably ineffective in patients with drug-resistant major depressive episode (Level B)					
<i>Anodal tDCS of the left DLPFC with right DLPFC cathode</i>					
Blumberger et al. (2012)	24 patients (drug-resistant MDD, HDRS-17 >21) (13 active, 11 sham)	Anode: left DLPFC (F3). Cathode: right DLPFC (F4)	2 mA, 20 min, 15 sessions (3 weeks; FU: 1 month)	No significant difference between active and sham tDCS.	II
Brunoni et al. (2013b)	103 patients (non-medicated MDD, very few drug-resistant, no bipolar, HDRS-17 >17) (27 active + Sertraline, 26 active + placebo, 24 sham + Sertraline, 26 sham + placebo)	Anode: left DLPFC (F3). Cathode: right DLPFC (F4)	2 mA, 30 min, 10 sessions (2 weeks), followed by 2 additional sessions (4 weeks; FU: 6 month)	Greater mood improvement (MADRS, HDRS-17, BDI) after active tDCS + sertraline compared to all other groups. Active tDCS only was significantly superior to placebo, but no difference between active tDCS and sertraline taken solely.	I
Brunoni et al. (2014a)	37 patients (non-medicated MDD, no bipolar, HDRS-24 >21) (20 active, 17 sham; combined with cognitive control therapy)	Anode: left DLPFC (F3). Cathode: right DLPFC (F4)	2 mA, 30 min, 10 sessions (2 weeks; FU: 2 weeks)	Greater mood improvement (HDRS-21, BDI) after active vs. sham tDCS only in older patients and those who presented better performance in the cognitive task	III

No recommendation for anodal tDCS of the left DLPFC with right DLPFC cathode in patients with depression.

BDI: Beck Depression Inventory; DLPFC: dorsolateral prefrontal cortex; FU: follow-up; HDRS: Hamilton Depression Rating Scale; MADRS: Montgomery-Åsberg depression rating scale; MDD: major depressive disorder.

Early studies used 20-min sessions of 1 mA anodal stimulation over the left DLPFC, the cathode being placed over the right supraorbital region (Fregni et al., 2006b,c). More recent trials support the use of longer sessions (30 min) of tDCS delivered at higher intensity (2 mA) with the cathode placed over the right DLPFC (Brunoni et al., 2013b; Valiengo et al., 2013). However, it remains to demonstrate that increasing the duration and intensity of stimulation necessarily leads to improve the therapeutic efficacy and to prolong the after-effects.

Since 2011, the antidepressant efficacy of tDCS was appraised in various meta-analyses, with the response and remission rates as primary and second outcome measures, including the calculation of effect sizes. In these works, an antidepressant response was usually defined as a 50% reduction in post-treatment scores on the Hamilton Depression Rating Scale (HDRS) or the Montgomery–Asberg Depression Rating Scale (MADRS). In the first meta-analyses, active tDCS showed no or only modest superiority compared to the sham condition (Kalu et al., 2012; Berlim et al., 2013), because of the small sample size of the included studies, a high degree of treatment resistance in at least two studies (Blumberger et al., 2012; Palm et al., 2012), or the use of tDCS as an add-on treatment to various antidepressants, leading to a ceiling effect. Furthermore, concomitant administration of mood stabilizers, benzodiazepines, or antiepileptics can influence tDCS-mediated effects on cortical excitability and theoretically might have reduced its therapeutic impact. More recent meta-analyses (Shiozawa et al., 2014; Meron et al., 2015) and an analysis of individual patient data (Brunoni et al., 2016a), including the large SELECT-TDCS trial conducted by Brunoni et al. (2013b), suggest superiority of active tDCS compared to sham treatment. In the SELECT-TDCS trial, the combination of tDCS with sertraline hydrochloride (50 mg/day) was superior to each treatment considered solely or to placebo, suggesting an additive interaction of tDCS and antidepressant pharmacotherapy. The effect of tDCS may be mediated by pharmacological modulation of serotonergic and noradrenergic neurons located in deep brain structures, although they are not directly affected by the superficial current flow generated by tDCS (Brunoni et al., 2014b). Alternatively, or additionally, serotonergic enhancement might boost the neuroplastic effects of anodal tDCS, thus resulting in synergistic effects (Nitsche et al., 2009b; Kuo et al., 2016).

Three studies have investigated the efficacy of long-term antidepressant treatment using tDCS (Dell'Osso et al., 2013; Martin et al., 2013; Valiengo et al., 2013). In a small series of 11 patients who completed a 3-month follow-up beyond a 10-day tDCS protocol, Dell'Osso et al. (2013) found that 45% of the patients were still responders at the last time point. The other studies reported a higher relapse rate when the repetition of the sessions was reduced from weekly to biweekly (Martin et al., 2013; Valiengo et al., 2013) or when the degree of treatment resistance was higher at the beginning of tDCS therapy (Valiengo et al., 2013). Other tDCS studies dealing with special issues, e.g., the influence of various biomarkers (brain-derived neurotrophic factor or cytokines), the augmentation effect with D-cycloserine administration, or the treatment of depression associated with human immunodeficiency virus infection or in the hemodialysis setting will be not reported here.

In conclusion, we have to distinguish between protocols using a cathode placed over the right orbitofrontal cortex and those using a cathode over the right DLPFC. Although the target electrode (anode) is placed over the left DLPFC in all cases, the tDCS current flow (electric field) through brain structures as well as the related network effects probably differs between the two montages. With the right orbitofrontal cathode, there is a sufficient amount of evidence (one positive class I and one positive class II studies issued from two independent groups) to make a recommendation for a

level of evidence B regarding the antidepressant efficacy of anodal tDCS of the left DLPFC on the basis of at least 10 daily sessions (2 mA, 20–30 min) in medicated or drug-free patients with major depressive disorder and no drug-treatment resistance. Conversely, there is also a sufficient amount of evidence (two negative class II studies issued from two independent groups) to make a recommendation for a level of evidence B regarding the absence of efficacy of the same tDCS protocol in patients with drug-resistant depression. Concerning tDCS montage with the anode over the left DLPFC and the cathode over the right DLPFC, no recommendation can be made because of insufficient level of evidence from data published by independent groups (two positive class I-II studies issued from the same group with very few cases of drug-resistant depression and one negative class II study from another group including patients with only drug-resistant depression).

13.2. Cognitive effects

Improvement of working memory, learning, and long-term memory by tDCS has been shown in various studies performed in healthy subjects (Kuo and Nitsche, 2012). In contrast, only few therapeutic studies report a specific assessment of the cognitive impact of tDCS in patients, including patients treated for depression. Improvement of working memory in depressed patients treated by tDCS was reported by Fregni et al. (2006c) using the digit-span test and by Boggio et al. (2007) using a go/no-go task. In studies with primary neuropsychological focus, anodal tDCS of the left DLPFC was found to improve working memory in depressed subjects (Oliveira et al., 2013; Wolkenstein and Plewnia, 2013) and to modify negative emotion processing in the emotional stroop task (Brunoni et al., 2014d). One study showed, however, that bifrontal tDCS reduced implicit learning in depressed subjects (Brunoni et al., 2013c). Improvement of cognition was also mentioned in single cases of tDCS-treated patients (Palm et al., 2009; Bueno et al., 2011). Conversely, other studies reported no significant cognitive changes induced by tDCS in depressed patients (Ferrucci et al., 2009; Loo et al., 2010, 2012; Martin et al., 2011; Palm et al., 2012). Finally, one study showed that the combination of cognitive control training (a new type of cognitive therapy) and tDCS has an augmenting effect on the improvement of depression (Segrave et al., 2014).

Concerning the impact of tDCS on cognitive symptoms of patients with major depression, a beneficial effect was reported in four class II studies, whereas one class I study and three class II studies were negative. In particular, two positive and one negative study emerged from the same SELECT-TDCS trial. Therefore, current data remain conflicting and no recommendation can be made for the use of tDCS of the DLPFC to improve cognitive symptoms in depressed patients. This conclusion is shared by an article recently published on this topic (Brunoni et al., 2016b).

14. Schizophrenia

Despite advances in psychopharmacology, the majority of treated patients with schizophrenia retain disabling symptoms. The most frequent drug-resistant symptoms are auditory verbal hallucinations (AVH) and various negative symptoms (e.g., avolition, alogia, or emotional withdrawal). Neuroimaging and neurophysiological studies have highlighted that these refractory symptoms may be linked to a fronto-temporal dysconnectivity. Negative symptoms and AVH have been related to a reduced brain activity in the right and left DLPFCs, while hyperactivity in the left temporo-parietal region is especially observed in patients with AVH. Using the concept of excitatory anodal stimulation versus inhibitory cathodal stimulation, it was hypothesized that anodal

Table 9
Repeated tDCS session protocols in schizophrenia.

Articles	Number and type of patients (protocol design)	Stimulation electrode location	Stimulation intensity, session duration, total number of sessions (protocol duration; follow-up)	Clinical results	Class
Anodal tDCS of the left DLPFC with left temporo-parietal cathode					
Brunelin et al. (2012a)	30 patients with AVH (15 active, 15 sham)	Anode: left DLPFC (between F3 and FP1). Cathode: left temporo-parietal junction (between T3 and P3)	2 mA, 20 min, 10 sessions (1 week; FU: 3 months)	Greater AVH reduction (mean (AHRs): –31% vs. –8%) after active vs. sham tDCS, remaining significant up to 3 months. Improvement of other schizophrenia symptoms, including negative symptoms (PANSS) after active vs. sham tDCS	II
Fitzgerald et al. (2014)	24 patients (11 bilateral, 13 unilateral)	Anode: left DLPFC (F3). Cathode: left temporo-parietal junction (TP3) (unilaterally or bilaterally F3 + F4/TP3 + TP4)	2 mA, 20 min, 15 sessions (3 weeks; no FU)	No difference in any schizophrenia symptoms (including AVH and negative symptoms) after active vs. sham tDCS at the end of the intervention	III
Mondino et al. (2015)	28 patients with AVH (15 active, 13 sham)	Anode: left DLPFC (between F3 and FP1). Cathode: left temporo-parietal junction (between T3 and P3)	2 mA, 20 min, 10 sessions (1 week; no FU)	Greater AVH frequency reduction (mean: –46% vs. +7.5%) after active vs. sham tDCS. Reduction in AVH frequency correlated with improvement in source monitoring performances (decrease of externalization bias)	II
Fröhlich et al. (2016)	26 patients with AVH (13 active, 13 sham)	3-electrode montage. Anode: left DLPFC (between F3 and FP1). Cathode: left temporo-parietal junction (between T3 and P3). Return reference: Cz	2 mA, 20 min, 5 sessions (1 week; no FU)	No difference in AVH reduction, (mean (AHRs): –24% vs. –34%) after active vs. sham tDCS. No effect on other symptoms	II
Mondino et al. (2016)	23 patients with AVH (11 active, 12 sham)	Anode: left DLPFC (between F3 and FP1). Cathode: left temporo-parietal junction (between T3 and P3)	2 mA, 20 min, 10 sessions (1 week; no FU)	Greater AVH reduction (mean (AHRs): –28% vs. –10%) after active vs. sham tDCS, correlated with a reduction of functional connectivity between the left temporo-parietal junction and anterior insula	II
No recommendation for anodal tDCS of the left DLPFC with left temporo-parietal cathode in schizophrenia					
Anodal tDCS of the left DLPFC with right supraorbital cathode					
Smith et al. (2015)	29 patients who were cigarette smokers (14 active, 15 sham)	Anode: left DLPFC (F3). Cathode: right supraorbital (Fp2)	2 mA, 20 min, 5 sessions (1 week; no FU)	Improvement in various scores of the MATRICS Consensus Cognitive Battery after active vs. sham tDCS, but no difference in PANSS scores, AVH, and cigarette craving between the two conditions	II
Palm et al. (2016b)	20 patients with negative symptoms (10 active, 10 sham)	Anode: left DLPFC (F3). Cathode: right supraorbital (Fp2-Af8)	2 mA, 20 min, 10 sessions (2 weeks; FU: 2 weeks)	Reduction of SANS and PANSS total scores after active vs. sham tDCS	II

No recommendation for anodal tDCS of the left DLPFC with right supraorbital cathode in schizophrenia.

AHRs: auditory hallucinations rating scale; AVH: auditory verbal hallucinations; DLPFC: dorsolateral prefrontal cortex; FU: follow-up; PANSS: positive and negative symptoms scale; SANS: Scale for the Assessment of Negative Symptoms.

tDCS of the left DLPFC (hypoactive) combined with cathodal tDCS of the left temporo-parietal junction (hyperactive) should alleviate negative symptoms and AVH in patients with schizophrenia ([Brunelin et al., 2012b](#); [Mondino et al., 2014](#)). In the same way, bilateral tDCS delivered to both prefrontal regions (left anode plus right cathode) should alleviate negative symptoms.

A PubMed search (keywords: tDCS AND schizophrenia) identified 116 papers, including 38 original clinical studies and 384 patients. Among these 38 papers, there were 19 case reports and 19 clinical studies with different tDCS protocols applied on samples of patients with various symptoms and group sizes. In fact, for the present study, we retained only 7 sham-controlled RCTs including at least 10 patients who received repeated daily sessions of active tDCS with the anode placed over the left DLPFC (between F3 and FP1 according to the International 10–20 system of EEG electrode placement) ([Brunelin et al., 2012a](#); [Fitzgerald et al., 2014](#); [Mondino et al., 2015, 2016](#); [Smith et al., 2015](#); [Fröhlich et al., 2016](#); [Palm et al., 2016b](#)). In two of these studies, the cathode was placed on the right supraorbital region ([Smith et al., 2015](#); [Palm et al., 2016b](#)) and they will be detailed later. In the remaining 5 studies, the cathode was placed over the left temporo-parietal junction (mid-point between T3 and P3) and the effects of this

bipolar montage over a large fronto-temporo-parietal region of the left hemisphere were assessed on various positive or negative symptoms of schizophrenia ([Table 9](#)).

Among these 5 studies, one double-blind sham-controlled RCT showed a significant reduction of AVHs following active tDCS compared to sham condition ([Brunelin et al., 2012a](#)). The protocol consisted of 10 daily sessions of tDCS (2 mA, 20 min) over two consecutive weeks. Clinical improvement was significant on persistent AVHs, but also on both negative and positive dimensions, assessed on the total positive and negative symptoms scale (PANSS) as a secondary outcome. The same group showed in partly overlapping samples that the reduction in AVHs following this type of tDCS protocol correlated with an improvement in source-monitoring performance ([Mondino et al., 2015](#)) and with a reduction of functional connectivity between the left temporo-parietal junction and anterior insula ([Mondino et al., 2016](#)). In contrast, little is known on the ability of this approach to improve cognitive functions, such as spatial working memory or speech processing, which are altered in patients with schizophrenia. A double-blind sham-controlled feasibility study confirmed the safety of this intervention in a series of 12 young patients with childhood-onset schizophrenia ([Mattai et al., 2011](#)). However, two replication

studies, including one comprising two small RCTs (unilateral and bilateral tDCS), and published by independent groups failed to demonstrate any clinically relevant effect of active vs. sham tDCS using this montage on AVHs and negative symptoms at the end of the intervention based on 15 tDCS sessions over three weeks (Fitzgerald et al., 2014) or 5 tDCS sessions over one week (Fröhlich et al., 2016). However, these studies suffered from various weaknesses, including small sample size, leaving room for further replication studies or large multicentric RCTs using multiple-session tDCS treatment in schizophrenic patients with the anode over the left DLPFC and the cathode over the left temporoparietal cortex. Meanwhile, we cannot make any recommendation about the efficacy of this montage to relieve schizophrenia symptoms, either positive or negative.

Other studies used a different electrode montage, with the anode still placed over the left DLPFC, but the cathode placed over the right supraorbital region. Using this montage, some beneficial results were reported in patient cases concerning the relief of negative symptoms of schizophrenia (Palm et al., 2013b) or catatonia (Shiozawa et al., 2013). In two controlled studies using this montage (Smith et al., 2015; Nienow et al., 2016), the cognitive impairment and deficits associated with schizophrenia were assessed, while schizophrenia symptoms were secondary outcomes or not assessed. These studies showed the positive effects on cognition of repeated sessions of anodal tDCS of the left DLPFC performed prior or during cognitive training. In the first study, with a parallel-arm design, 29 patients (14 in the active group and 15 in the sham group) received 5 sessions of anodal tDCS (2 mA, 20 min) of the left DLPFC (with right supraorbital cathode) over one week (Smith et al., 2015). A significant cognitive improvement was observed at the end of the intervention after active vs. sham tDCS in composite, working memory and attention-vigilance scores of the MATRICS Consensus Cognitive Battery. However, there were no differences between the two tDCS conditions regarding the PANSS scores (including AVH and negative symptoms) and cigarette smoking or craving. A single-blind, sham-controlled, proof-of-concept study also addressed cognitive issues in 10 schizophrenic patients receiving 28 sessions (two sessions each week) of tDCS combined with cognitive training (Nienow et al., 2016). The 6 patients who received active stimulation with the anode over the left DLPFC and the cathode over the contralateral supraorbital area showed significant more improvement on word or picture 2-back tasks compared to the 4 patients who received sham stimulation. However, schizophrenia symptoms were not assessed. Conversely, the most recent study using this montage had the Scale for the Assessment of Negative Symptoms (SANS) as the primary outcome measure (Palm et al., 2016b). This double-blind sham-controlled study with parallel-arm design (10 patients per arm) showed a significant reduction of 36% of negative symptoms on SANS after 10 active stimulations compared to a reduction of 0.7% in the sham group. As secondary outcome, PANSS sum scores also decreased significantly more after active (−23.4%) than sham stimulation (−2.2%). However, the results of the two sham-controlled studies using this montage (Smith et al., 2015; Palm et al., 2016b) being conflicting (Table 9), no recommendation can be made for the use of anodal tDCS of the left DLPFC with a contralateral orbitofrontal cathode in schizophrenia, even regarding cognitive deficits.

Finally, some results were reported in this domain, still with the anode over the left DLPFC but with other cathode placements. For example, with the cathode placed over the right DLPFC (bihemispheric DLPFC stimulation), a small RCT, including 15 patients and specifically addressing the treatment of negative symptoms, showed a significant decrease in PANSS total score and negative subscale after active stimulation compared to sham condition (Gomes et al., 2015). Using a cathode placed over the right deltoid

muscle, an open-label study of 9 patients with negative symptoms also found an improvement of 24% in the PANSS negative subscale after anodal tDCS of the left DLPFC (Kurimori et al., 2015). The results obtained with these montages, non-replicated yet, cannot be considered for making recommendation.

15. Substance abuse, addiction and craving

Addiction to substances such as alcohol, drugs, nicotine, or food, is a major health issue, because of the difficulty to achieve a permanent cure with a high rate of relapses, despite detoxification and pharmacological or psychological interventions (Fant et al., 2009; Heinz et al., 2009). The rationale of using tDCS as a treatment for substance addiction and craving is that the DLPFC, which plays a major role in top-down inhibitory control mechanisms and reward mechanisms, was claimed to be dysfunctional in these disorders (Goldstein and Volkow, 2002; Wilson et al., 2004).

A PubMed search (keywords: tDCS AND addiction OR craving) identified 80 papers, including 32 original clinical studies and 583 subjects. No safety problems emerged in these studies. There were 19 studies including at least 10 patients, but mostly based on single tDCS sessions with immediate or short-term assessment. In fact, we only identified 4 sham-controlled studies with at least 10 patients who received repeated daily sessions of the same type of active tDCS, i.e. a bihemispheric stimulation of the DLPFC with the anode on the right (F4) and the cathode on the left hemisphere (F3) (Boggio et al., 2009b; Fecteau et al., 2014; Klauss et al., 2014; Batista et al., 2015) (Table 10). The analyzed results cover patients addicted to alcohol, cocaine, crack, or smoking. All these studies were positive regarding the effect of active tDCS, either in the resulting quality of life (Klauss et al., 2014; Batista et al., 2015) or in craving scores (Boggio et al., 2009b; Fecteau et al., 2014; Batista et al., 2015). According to these four positive class II studies issued from two independent teams, we can make a recommendation for a level of evidence B regarding the efficacy of bihemispheric tDCS of the DLPFC (right anode + left cathode) to reduce craving in patients with various types of addiction. However, this statement must be tempered by the fact that studies concerning alcohol abuse, crack-cocaine abuse, and smoking were pooled together, with results obtained on different outcome variables. Nevertheless we want to keep this statement, since a common mechanism of action certainly underlies all the results obtained with this given montage in patients who all have an addiction. This conclusion is reinforced by a recent neurophysiological and neuroimaging study showing that abstinence provided by bihemispheric tDCS of the DLPFC using this specific montage (right anode + left cathode) could involve functional changes in the ventral medial prefrontal cortex in both alcoholics and crack-cocaine users (Nakamura-Palacios et al., 2016).

It is interesting to note that this montage is similar to the one proposed in the treatment of tinnitus, but opposed to the one proposed in the treatment of depression (anodal tDCS of the left DLPFC with right DLPFC cathode) (see previous chapters). In fact, as aforementioned, Faber et al. (2012) found a beneficial effect on tinnitus regardless of the direction of the montage between the two hemispheres, but tinnitus-associated depression was preferentially relieved by placing the anode over the left DLPFC, whereas anxiety was preferentially relieved by placing the anode over the right DLPFC.

Actually, in alcoholics, one study showed a reduction of craving for visual alcohol cues after a single session of active bihemispheric tDCS of the DLPFC, similarly for a right anode + left cathode montage and a left anode + right cathode montage (Boggio et al., 2008b). Conversely, the same team showed that only the right

Table 10
Repeated tDCS session protocols in addiction/craving.

Articles	Number and type of patients (protocol design)	Stimulation electrode location	Stimulation intensity, session duration, total number of sessions (protocol duration; follow-up)	Clinical results	Class
<i>Alcohol</i>					
Klauss et al. (2014)	33 alcoholics (16 active, 17 sham)	Anode: right DLPFC (F4). Cathode: left DLPFC (F3)	2 mA, 2 × 13 min (separated by a 20-min rest interval without stimulation), 5 sessions (1 week; FU: 6 months)	Improvement in overall perception of quality of life after active vs. sham tDCS, but no difference in craving scores, frontal function, global mental status, and anxiety-depression symptoms. At 6 months, alcohol-abstinent subjects were more numerous after active vs. sham tDCS (8/16 vs/ 2/17)	II
<i>Crack-Cocaine</i>					
Batista et al. (2015)	36 crack-cocaine users (17 active, 19 sham)	Anode: right DLPFC (F4). Cathode: left DLPFC (F3)	2 mA, 20 min, 5 sessions (3 weeks; FU: 1 week)	Improvement in craving scores, anxiety, and overall perception of quality of life after active vs. sham tDCS. In addition, craving scores decreased linearly over 4 weeks	II
<i>Smoking</i>					
Boggio et al. (2009b)	27 smokers (13 active, 14 sham)	Anode: right DLPFC (F4). Cathode: left DLPFC (F3)	2 mA, 20 min, 5 sessions (1 week; no FU)	Decrease in the number of cigarettes smoked after active vs. sham tDCS in the week of intervention. In addition, cumulative reduction of craving for cue-provoked smoking after active tDCS	II
Fecteau et al. (2014)	12 smokers (crossover)	Anode: right DLPFC (F4). Cathode: left DLPFC (F3)	2 mA, 30 min, 5 sessions (1 week; FU: 4 days)	Decrease in the number of cigarettes smoked after active vs. sham tDCS, lasting up to 4 days after the end of the intervention. Smokers rejected more often offers of cigarettes with reward sensitive effects after active tDCS	II

Recommendation: combined anodal tDCS of the right DLPFC and cathodal tDCS of the left DLPFC is probably effective in addiction/craving (Level B).
DLPFC: dorsolateral prefrontal cortex; FU: follow-up.

anode + left cathode montage was significantly associated with a reduction of craving for marijuana, while both montages increased the propensity for risk-taking in chronic marijuana users (Boggio et al., 2010). Other working groups interestingly found that only the right anode + left cathode montage was specifically able to reduce the risk-taking behavior in 18 dependent cocaine users (Gorini et al., 2014) and 18 cigarette smokers (Pripfl et al., 2013). This right anode + left cathode montage, applied in single or multiple tDCS sessions (2 mA, 20 min, 5 days for one week) was found to positively impact cognitive processing related to crack-related visual cues in 13 crack-cocaine users (Conti and Nakamura-Palacios, 2014). Pripfl and Lamm (2015) also showed that a single session of bihemispheric tDCS of the DLPFC with the right anode + left cathode montage (and not the reverse montage) could reduce negative affect in emotion appraisal but not modulate nicotine craving-cue appraisal in 20 smokers. Finally, Kekic et al. (2014) reported that a single tDCS session with the right anode + left cathode montage over the DLPFC improved craving scores for sweet but not savoury foods in 17 patients with food craving. The participants that exhibited more reflective choice behaviour were more susceptible to the anti-craving effects of tDCS than those that displayed more impulsive choice behaviour. However, no difference in food consumption was observed after active vs. sham tDCS. Conversely, one week of daily anodal tDCS delivered to the right DLPFC (but with the cathode placed in the left supraorbital region) was found to reduce overall caloric intake by 14% in comparison with sham stimulation in 14 subjects, which however do not meet the criteria of eating disorder (Jauch-Chara et al., 2014).

Other studies used a tDCS montage with the anode over the left DLPFC and a cathode over the contralateral supraorbital or shoulder region. Using this montage, a transient improvement on clinical and electrophysiological features of craving was observed in alcoholics after a single active tDCS session (Nakamura-Palacios et al., 2012; den Uyl et al., 2015) or a series of 5 sessions (once a week for five consecutive weeks) (da Silva et al., 2013). In smokers, anodal stimulation of the left DLPFC with cathode placed over the contralateral supraorbital region was found to reduce the negative affect correlated with nicotine dependence without any change on

cigarette craving in one single-session study (Xu et al., 2013) or to improve the ability to resist smoking in another single-session study (Falcone et al., 2016). Obviously, these results are still too preliminary to make any recommendation for the use of anodal tDCS of the left DLPFC with the cathode over the right orbitofrontal region in craving. Finally, the reverse tDCS montage, with the anode over the right DLPFC and the cathode over the left supraorbital region, was recently shown to be able to reduce food craving (Ljubisavljevic et al., 2016). A single session could produce immediate effects, while the clinical improvement could last for a month after a 5-day protocol. These results remain to be replicated.

16. Other psychiatric disorders

Regarding clinical applications of tDCS in psychiatric disorders other than depression, schizophrenia and addiction, there are only very limited data available in the literature. A PubMed search (keywords: tDCS AND obsessive compulsive disorder) identified 17 papers, including 5 original clinical studies and 12 patients. There were 4 single case reports and only one open-label study performed on 8 patients with the cathode placed over the left orbitofrontal cortex and the anode placed over the right cerebellum (Bation et al., 2016). A PubMed search (keywords: tDCS AND post-traumatic stress disorder) identified 5 papers, including only one pilot study of 4 patients (Saunders et al., 2015). A PubMed search (keywords: tDCS AND autism) identified 36 papers, including 6 original clinical studies and 64 patients. Among these 6 papers, there were 2 single case reports and 2 RCTs issued from the same team assessing the effect of either a 5-day protocol on clinical scores or a single session on EEG parameters in a series of 20 patients (Amatachaya et al., 2014, 2015). The montage used was an anode placed over the left DLPFC (F3) with a cathode on the right shoulder. Finally, a PubMed search (keywords: tDCS AND attention-deficit hyperactivity disorder) identified 24 papers, including 2 original clinical studies (single-session studies) and 80 patients. One study (60 patients) did not find significant differences between active and sham tDCS regarding the effect of

bihemispheric tDCS of the DLPFC (left anode + right cathode) on behavioral performance in go/no-go tasks (Cosmo et al., 2015). Conversely, the other study (20 patients) showed that anodal tDCS of the left DLPFC (with right supraorbital cathode) increased the proportion of correct responses in go/no-go tasks, whereas cathodal tDCS of the left DLPFC increased the inhibition accuracy (Soltaninejad et al., 2016). Obviously, reported results are too preliminary to make any recommendation for the use of tDCS in all these psychiatric conditions.

17. At-home do-it-yourself DCS and neural enhancement

One of the main advantages of tDCS as a therapeutic device is to be a low-cost, small-size, and patient-wearable equipment. Also, it allows distribution of machines for home use, which is not the case for rTMS. Although therapeutic effects may last beyond the time of stimulation when using NIBS techniques because of neural plasticity processes, the treatment of a chronic disease always requires repeated sessions in a maintenance protocol. Considering rTMS, this is resulting in multiple trips and visits for the patient to be stimulated, generating fatigue and costs, and reducing compliance. Considering tDCS, at-home application is feasible and potentially more comfortable and less tiring for the patient. At-home tDCS trials have been already reported as case reports for the treatment of AVH (Andrade, 2013) or chronic myofascial pain (Pérez-Borrogo et al., 2014), series of patients with trigeminal neuralgia (Hagenacker et al., 2014) or tinnitus (Hyvärinen et al., 2016), or are currently under investigation in patients with chronic pain (O'Neill et al., 2015) or MS (Kasschau et al., 2015). One group also used tDCS as an add-on intervention combined with physical therapy to promote motor recovery in patients impaired by intracerebral hemorrhage (Mortensen et al., 2016). Recommendations have even been recently proposed for a safe use of remotely-supervised at-home tDCS (Charvet et al., 2015), highlighting training of the user or caregiver, medical supervision, monitoring of compliance, and assessment of the clinical benefit or side-effects. However, an uncontrolled domiciliary utilization of tDCS devices exposes the patient to potential adverse events caused by misuse or overuse, e.g., skin burns (Wang et al., 2015) or unnecessary or dangerous repetition of the sessions.

Because of the wide diffusion of tDCS or tDCS-like machines that can be bought freely on the internet, it will be difficult to restrict the use of these machines and ensure correct application. This also refers to the topic of “neuroenhancement”, which is however beyond the scope of this present work, as it relates to improving the capacities of normal subjects and not to treat pathological conditions. In this context of free access to technology, neuroenhancement by tDCS is the subject of many ethical and regulatory debates (Hamilton et al., 2011; Cohen Kadosh et al., 2012; Heinrichs, 2012; Santarnecchi et al., 2013; Cabrera et al., 2014; Fitz and Reiner, 2015; Maslen et al., 2015; Wexler, 2016) and scientific controversies. In fact, theoretically, tDCS may have the capacity to “enhance” attention, learning, endurance, motor execution, memory, or other higher-order processes such as decision-making, risk-taking, or problem-solving (Levasseur-Moreau et al., 2013; Brem et al., 2014; Coffman et al., 2014). However, tDCS experts' opinions are not unequivocal on this topic, as shown by two recent surveys (Shirota et al., 2014; Riggall et al., 2015). In fact, modifying neural activity by NIBS does not always go in the expected direction in a “normal” human brain. For example, one study showed that the improvement of cognitive performance by testing repetition was reduced in healthy subjects after a single session of active tDCS over the DLPFC (bilateral or unilateral anodal stimulation with the cathode placed at Cz) compared to the sham procedure (Sellers et al., 2015). Specifically, the reduction in

test–retest improvement was observed on the Full Scale Intelligence Quotient and the Perceptual Reasoning Index of the Wechsler Adult Intelligence Scale. Another study showed that the accuracy performance in a working memory task was significantly decreased during and after a single session of tDCS over the DLPFC using a commercial tDCS machine that is freely available on the internet as a cognitive enhancer (Steenbergen et al., 2016). Therefore, there is a need for maintaining a level of technical and scientific excellence and considering regulatory issues to not discredit this therapeutic perspective. In this context, the International Federation of Clinical Neurophysiology (IFCN) recently warns against the use of DIY devices and methods of NIBS unless they have shown both efficacy and safety (see recommendation in the following document: http://www.ifcn.info/uploadfiles/documents/2015/Using_tES_devices_as_DIY_FINAL_13Dec15.pdf).

18. Perspectives of targets other than cortical (cerebellum and spinal cord)

Although this work is intended to be a guideline on the indications of tDCS applied to the cerebral cortex, readers should be informed that research currently develops to explore the possibility of using transcutaneous DC stimulation on other neural targets, such as cerebellum and spinal cord, in order to promote functional neural changes (Piori et al., 2014). This issue will be briefly addressed.

18.1. Cerebellar tDCS

Because the cerebellum plays a major role in several brain functions, cerebellar stimulation could be a preferential way of therapeutic intervention in many pathological conditions. Weak DC delivered transcutaneously in humans over the cerebellum for minutes elicits prolonged changes in neurophysiological and behavioural responses related to cerebellar functions (Ferrucci and Piori, 2013; Grimaldi et al., 2014a). Theoretical considerations and modelling studies suggest that the electric field generated by tDCS can reach the cerebellum when using an appropriate montage (Parazzini et al., 2014b). The induced effects arise from functional changes in the stimulated cerebellum, although transynaptic or antidromic changes may also occur in connected cerebral or brainstem structures.

There is already reported evidence that cerebellar tDCS can induce neurophysiological, functional, and clinical effects related to DC-induced neuroplasticity and neurotransmitter changes (Ferrucci et al., 2015; Grimaldi et al., 2016). For example, cerebellar tDCS was found to influence cerebello-thalamo-cortical inhibitory projections (Galea et al., 2009), human associative plasticity assessed by the paired-associative stimulation paradigm (Hamada et al., 2012), somatosensory mismatch negativity (Chen et al., 2014) conditioned eyeblink responses (Zuchowski et al., 2014), gait adaptation (Jayaram et al., 2012), motor learning (Galea et al., 2012; Dutta et al., 2014; Hardwick and Celnik, 2014; Herzfeld et al., 2014), and cognitive functions, such as memory and emotion (Ferrucci et al., 2008b, 2012, 2013; Boehringer et al., 2012; Pope and Miall, 2012; Macher et al., 2014). These results have been obtained in healthy humans and could have clinical interest, especially in patients with disorders involving cerebellar dysfunction such as ataxia, Parkinson's disease, autism and schizophrenia (Yeganeh-Doost et al., 2011; Massaquoi, 2012; Wu and Hallett, 2013).

There are only preliminary data of the application of cerebellar tDCS in patients (Grimaldi and Manto, 2013; Bradnam et al., 2014, 2015; Gironell et al., 2014; Grimaldi et al., 2014b; Minichino et al., 2014, 2015; Sadnicka et al., 2014; Benussi et al., 2015; Bation et al.,

2016; Ferrucci et al., 2016). Much work remains to be done to design further therapeutic studies using cerebellar tDCS, according to the parameters of stimulation (electrode montage, polarity), the possible mechanisms of action, and the underlying pathological conditions and interactions with ongoing drug treatments.

18.2. Transcutaneous spinal direct current stimulation

Invasive high-frequency epidural electrical spinal cord stimulation (SCS) has been used for more than 30 years to treat a variety of pain syndromes (Grabow et al., 2003; Mailis-Gagnon et al., 2004; Frey et al., 2009). Involving totally different mechanisms of action, a noninvasive approach of spinal cord neuromodulation was recently developed, using transcutaneous DC stimulation in humans (Cogiamanian et al., 2008, 2012).

The application of anodal DC at the thoracic level (2.5 mA for 15 min with the cathode placed at the right shoulder) selectively reduced the amplitude of the cervicomedullary P30 component of the somatosensory evoked potentials to posterior tibial nerve stimulation (Cogiamanian et al., 2008) as well as laser evoked potentials after foot stimulation (Truini et al., 2011) or nociceptive withdrawal reflex (Cogiamanian et al., 2011; Perrotta et al., 2016). These results provide evidence that transcutaneous spinal direct current stimulation (tsDCS) is able to interfere with spinal cord conduction properties and to modulate conduction in the lemniscal and spino-thalamic pathways. At present, there is also increasing evidence that tsDCS is able to induce persisting changes in properties of spinal sensory or motor neurons (Winkler et al., 2010; Lim and Shin, 2011; Lamy et al., 2012; Hubli et al., 2013; Niérat et al., 2014). The resulting excitability changes induced by tsDCS may also extend to corticospinal tracts or even intracortical circuits (Bocci et al., 2015a,b,c).

To date, the precise mechanisms underlying these neuromodulatory effects remain speculative, although one modelling study improves the understanding of the spatial distribution of the current density generated by tsDCS (Parazzini et al., 2014a). Nevertheless the possibility of influencing conduction along the ascending spinal pathway as well as spinal circuitries is vghghngngpain syndrome, e.g., restless leg syndrome (Heide et al., 2014) and the neurorehabilitation of motor disorders, especially spasticity or poststroke gait impairment (Picelli et al., 2015).

19. Perspectives of treatment by transcranial electrical stimulation methods other than tDCS (tACS, tRNS)

Although the present work addresses tDCS results, we should also mention that future developments with potential therapeutic application might regard other non-invasive neuromodulation techniques using low-intensity transcranial electrical stimulation. We briefly present these other techniques, namely tACS and tRNS, which are for now the subject of relatively few clinical studies. Taking into account all physical possibilities, an indefinite number of transcranial electrical stimulation protocols exists. Rather arbitrarily determined protocols have been tried over the last century, mainly deriving from the Franco-Russian experience of “electrosleep” or “electroanesthesia” (Guleyupoglu et al., 2013). Most of the complex historical stimulation protocols are proprietary commercial “blends” and will probably not survive the test of time against physically simpler and better evaluated protocols such as tDCS or sinusoidal tACS (Paulus, 2011). In case of tDCS, first clinical descriptions date as early as 1801, one year after the invention of the voltaic pile. An earlier attempt of modulating slow EEG oscillations by tACS was performed during sleep, but tACS was applied with tDCS overlay, leaving until today unclear whether the DC or the AC component provided the resulting effect (Marshall et al.,

2006). Then, the first investigation with pure sinusoidal motor cortex tACS delivered at 10 Hz produced only small aftereffects on implicit motor learning (Antal et al., 2008). This was probably due to the low intensity of stimulation (0.4 mA), which was chosen to avoid retinal phosphenes via the frontal return electrode. Since a couple of years, tACS was applied in disease context, first in movement disorders (Angelakis et al., 2013) and tinnitus (Vanneste et al., 2013a,b), and more recently to modulate tremor by targeting the cerebellum (Mehta et al., 2014).

Two different goals have to be differentiated when looking at tACS effects, first regarding entrainment with ongoing brain rhythm and second regarding induction of aftereffects. In the context of the present review, the latter seems to be the most interesting since this would avoid wearing the stimulation electrode all day for therapeutic purposes. The problem of the necessity for continuous stimulation was pointed out by a closed-loop tACS approach using specified phase alignments to suppress parkinsonian tremor by about 50% (Brittain et al., 2013). This is also a requirement for the application of alternating fields at very high intensity and frequency for therapeutic purpose in a disease justifying substantial efforts for treatment, namely the treatment of glioblastoma (Swanson et al., 2016). The upper frequency limit of tACS has not yet been determined and it touches e.g. the question if mobile phone emission can influence brain function. In fact, continuous tACS at 200 kHz could selectively destroy dividing cells by targeting the inhomogeneous fields present at the bridge separating the daughter cells that interfere with spindle tubulin orientation and induce dielectrophoresis (Kirson et al., 2007). Conversely, the role of tACS frequencies in the low kHz range remains to be investigated. A first study showed that 2 and 5 kHz tACS protocols were particularly efficacious in inducing a sustained increase in MEP amplitude up to 30–60 min after the intervention (Chaieb et al., 2011). Within this frequency, tACS appears too fast to entrain brain circuit oscillations, and therefore the stimulation probably directly interferes with cortical excitability via neuronal membrane activation changes.

A protocol of 140 Hz tACS delivered at 1 mA for 10 min can produce aftereffects comparable in duration to those induced by anodal tDCS (Moliadze et al., 2010). This frequency complies with the so-called “ripple frequency”, which has a function in encoding memory in the hippocampus. Interestingly it is about the same frequency which was empirically found to be optimally suited for DBS therapeutical effects in movement disorders (130 Hz). In the context of tACS, stimulation intensity plays a critical role to promote either excitation or inhibition of the neural circuits (Moliadze et al., 2012) and not electrode polarity as for tDCS. A deeper understanding is requested to determine how electrode size, shape, or montage, as well as stimulation frequency and intensity (Moliadze et al., 2012) and the initial state of the brain and its susceptibility to resonance effects (Feurra et al., 2013) may interfere in a complex manner in the emergence of tACS effects beyond the simple process of oscillation entrainment or spiking resonance (Reato et al., 2013; Schmidt et al., 2014).

Although motor cortex excitability parameters assessed by TMS, e.g., motor threshold or MEP size measurement, provides widely used biomarkers, their value in predicting behavioural changes induced by tACS remains highly speculative. For example, 140 Hz tACS was very efficient in influencing MEP size, whereas implicit motor learning was rather facilitated by 250 Hz tACS (Moliadze et al., 2010). Frequency-specific effects can be circumvented by performing tRNS, which was introduced by Terney et al. (2008) as a novel method of transcranial electrical stimulation. However, a random noise spectrum using frequencies ranging from 100 to 640 Hz led essentially to the same results as 140 Hz tACS or anodal tDCS, i.e. a consistent increase in motor cortex excitability (Terney et al., 2008). In fact, tRNS may provide larger

MEP size increase and anodal tDCS longer MEP size increase compared to sham, suggesting different underlying mechanisms of action (Moliadze et al., 2014). As tACS, tRNS was also applied in disease context since a couple of years, to provide “therapeutic” improvement, such as the relief of neuropathic pain (Alm and Dreimanis, 2013; Palm et al., 2016a), psychiatric symptoms (Palm et al., 2013a; Haesebaert et al., 2014), or tinnitus (Vanneste et al., 2013a,b; Claes et al., 2014; Joos et al., 2015). These reported clinical effects should be specifically assessed, but largely remain preliminary before being replicated by independent groups in sham-controlled studies.

20. Summary of recommendations

This work presents for the first time a comprehensive evidence-based analysis of the reported clinical efficacy of various tDCS montages that could lead to therapeutic applications in the neurological, otorhinolaryngological, and psychiatric domains. According to this synthesis, there is a sufficient level of evidence to make recommendations for the efficacy of specific tDCS montages in several clinical indications, as summarized in Table 11.

To date, a Level A recommendation has not been achieved so far for any clinical indication. In contrast, a Level B recommendation (probable efficacy) is conferred for the clinical effect of: (i) anodal tDCS of the left M1 (defined as C3 location in the International 10–20 system of EEG electrode placement) with the cathode over the right orbitofrontal region in fibromyalgia; (ii) anodal tDCS of the left DLPFC (F3) with the cathode over the right orbitofrontal region in non-drug-resistant major depressive episodes; (iii) anodal tDCS of the right DLPFC with the cathode over the left DLPFC in addiction/craving, although this statement covers different clinical conditions and outcome variables. A Level C recommendation (possible efficacy) is conferred for the clinical effect of anodal tDCS of the motor cortex of the left hemisphere or contralateral to pain side with the cathode over the right orbitofrontal region in patients

with chronic neuropathic pain at the lower limbs secondary to traumatic or medical spinal cord lesion.

Conversely, a Level B recommendation (probable inefficacy) is conferred for the absence of clinical effect of: (i) anodal tDCS of the left temporal cortex (between C3 and T3/T5) with the cathode over the right orbitofrontal region in chronic tinnitus; (ii) anodal tDCS of the left DLPFC (F3) with the cathode over the right orbitofrontal region in drug-resistant major depression. Finally, in clinical conditions where no recommendation was proposed, it must be underlined that the absence of evidence should not be taken as evidence for the absence of effect.

Further controlled studies in all potential therapeutical indications are obviously needed to extend and confirm the present recommendations. The term “recommendation” used in this work should not be misinterpreted. Our objective was to “recommend” a type of tDCS protocol in a given clinical situation according to the level of evidence of its “real” efficacy, comparing active vs. sham condition. Our methodology was not that of a meta-analysis using all data published in a statistical way, but was based on the existence of results replicated by independent teams on a representative sample of patients who received multiple sessions of active stimulation. For example, the beneficial results provided by a given tDCS protocol in a specific indication but only reported by one team and not replicated by independent teams did not lead to a recommendation, whereas such results might have a significant weight in a meta-analysis. In addition, a high level of evidence of efficacy (comparing active vs. sham condition) should not open the door to clinical use in daily routine practice without any limitations. The first of these limitations is to precisely design the tDCS protocol to apply, especially in terms of session duration and repetition or combined therapy. Our work was intended to present evidence-based guidelines, not practical guidelines to codify the daily use of tDCS therapy. The second limitation is the fact that a “significant” effect of active stimulation compared to sham control may be statistically relevant but not clinically meaningful in daily

Table 11
Summary of recommendations on tDCS efficacy according to clinical indication.

Chronic neuropathic pain of the lower limbs due to spinal cord lesion	Anodal tDCS of left M1 (or contralateral to pain side) is possibly effective in case of spinal cord lesion (Level C). No recommendation in case of peripheral nervous system lesion
Chronic non-neuropathic oral, facial, low back, abdominal, or pelvic pain	No recommendation for anodal tDCS of left M1 (or contralateral to pain side)
Fibromyalgia	Anodal tDCS of left M1 is probably effective (Level B)
Migraine	No recommendation for anodal tDCS of the left M1 or cathodal tDCS of V1
Postoperative pain	No recommendation for anodal tDCS of M1 or the left DLPFC
Parkinson's disease (motor symptoms)	No recommendation for anodal tDCS of the motor cortex
Parkinson's disease (cognitive symptoms)	No recommendation for anodal tDCS of the left DLPFC
Dystonia (focal or generalized)	No recommendation for anodal or cathodal tDCS of the motor cortex
Motor stroke	No recommendation for anodal tDCS of the ipsilesional motor cortex in acute, postacute, or chronic stage No recommendation for cathodal tDCS of the contralesional motor cortex in postacute stage No recommendation for bihemispheric tDCS of the motor cortex (ipsilesional anode + contralesional cathode) in chronic stage
Nonfluent poststroke aphasia	No recommendation for anodal tDCS of left Broca's area or Wernicke's area or cathodal tDCS of their right homologous region in postacute or chronic stage
Multiple sclerosis (fatigue or cognitive disorders)	No recommendation for anodal tDCS of sensory or motor cortex or the left DLPFC
Multiple sclerosis (sensory or motor symptoms)	No recommendation for anodal tDCS of M1
Epilepsy	No recommendation for cathodal tDCS of the epileptic focus or anodal tDCS of the left DLPFC
Disorders of consciousness	No recommendation for anodal tDCS of the left DLPFC
Alzheimer's disease	No recommendation for anodal tDCS of the left DLPFC or the temporoparietal cortex
Tinnitus	Anodal tDCS of the left temporoparietal cortex is probably ineffective (Level B) No recommendation for bihemispheric tDCS of the DLPFC (right anode + left cathode)
Depression	Anodal tDCS of the left DLPFC with right orbitofrontal cathode is probably effective in non-drug-resistant major depression (Level B) and probably ineffective in drug-resistant major depression (Level B) No recommendation for bihemispheric tDCS of the DLPFC (left anode + right cathode)
Schizophrenia (AVH or negative symptoms)	No recommendation for anodal tDCS of the left DLPFC with left temporoparietal or right supraorbital cathode
Addiction/craving	Bihemispheric tDCS of the DLPFC (right anode + left cathode) is probably effective in addiction/craving (alcohol, drugs, smoking) (Level B) No recommendation for anodal tDCS of the left DLPFC with right supraorbital cathode

“No recommendation” means the absence of sufficient evidence to date, but not the evidence for an absence of effect.

living or in terms of quality of life. Therefore, it remains to be determined how to optimize tDCS protocols and techniques to give them “therapeutic relevance” in routine clinical practice. The safety profile of tDCS is very high, as far as explored, with regard to the currently applied protocols (Bikson et al., 2016). Adverse effects are limited to mild headache or local sensory discomfort (Poreisz et al., 2007; Brunoni et al., 2011; McFadden et al., 2011; Kessler et al., 2012). In practice, the main issue is to avoid local skin burns by limiting excessive current density according to electrode size and shape, keeping a good homogeneous contact between the electrodes and the skin using gel, cream, or appropriately large, wet electrodes (Loo et al., 2011; Palm et al., 2014b). In this context, technical guidelines have been recently proposed by a group of experts to ensure a proper use of tDCS protocols (Woods et al., 2016).

Our work has other limitations. First, our literature search strategy was based on only one database (PubMed), but this is one of the main international databases of references on life sciences and biomedical topics. In addition, the research was conducted by experts in the field. Therefore, it is unlikely that original published data of importance can miss in this work. More importantly, we cannot rule out the impact of publication bias on our analysis, which corresponds to the fact that trials with statistically significant beneficial results are most likely to be submitted and published than trials with “negative” or non-significant results. This is a well known problem for any conclusion reported in literature reviews or meta-analyses based only on published studies, which should be considered with caution, even when analysis methods seem very stringent (Easterbrook et al., 1991). Finally, it is important to underline that our analysis was based on arbitrary criteria regarding the number of patients receiving active treatment needed to be included (≥ 25 in a class I study and ≥ 10 in a class II study), which could be considered relatively small to people outside of this field of research. The results of the analyses and therefore the recommendations would have changed if the number of patients receiving active treatment needed to be included was set at a higher value (e.g., ≥ 15 –20 patients in the “active” arm rather than ≥ 10 patients), mostly because few studies would exceed this cutoff. However, the main interest and justification of the method used in this work are to be identical to the previously published recommendations for therapeutic use of rTMS (Lefaucheur et al., 2014) and thus allowing comparisons.

We must be aware of the existence of current technical developments, focussing on new designs of electrode montages, shapes or sizes, resulting in new “geometries” of electric field distribution within the brain (Saturnino et al., 2015), or on combined approaches with neuroimaging (e.g., fiber tracking) and high-resolution EEG to improve targeting. Such developments, as well as a better characterization of stimulation intensity, duration, and session repetition requirements, may help to reduce the large interindividual variability in tDCS efficacy that currently renders the average clinical responses rather modest. The use of tDCS should also be considered as an adjunctive therapy in combination with medication or non-pharmacological therapy, with the aim of improving or accelerating the efficacy of these treatments. However, various applications of tDCS in combined protocols with concomitant interventions showed no additional impact of tDCS, possibly due to a ceiling effect, as shown for the combination of tDCS and robot-assisted training in motor rehabilitation of stroke patients (Geroïn et al., 2011; Hesse et al., 2011; Triccas et al., 2015). Furthermore, different drug treatments may even reduce tDCS efficacy, leading to a worse outcome compared to unmedicated patients, as shown for the use of benzodiazepines in depressed patients treated by 5 tDCS sessions, with the anode over the left DLPFC and the cathode over the right DLPFC (Brunoni et al., 2013a).

To conclude, there are pros and cons for the different NIBS techniques, such as tDCS and rTMS, applicable in clinical conditions. The respective place of these techniques remains to be determined in the available armamentarium and the decision tree for the treatment of neuropsychiatric diseases. However, it is likely that the indications of NIBS techniques will increasingly develop in routine clinical practice in the future, mostly due to their excellent ratio between benefit and risk. These guidelines pave the way for the therapeutic application of tDCS by showing already acquired evidence of efficacy of this technique in the current literature.

Conflict of interest

Michael A. Nitsche is member of the advisory board of Neuro-electrics, Barcelona, Spain. Simone Rossi have received grants from EBNeuro S.p.A, Florence, Italy and travel support from MagVenture, Farum, Denmark and Magstim Co., Whitland, Carmarthenshire, UK, respectively. Walter Paulus is on the scientific advisory board of EBS technologies, Berlin, Germany. Frank Padberg has received speaker honorarium from Mag&More GmbH, Munich, Germany and equipment support from neuroConn GmbH, Ilmenau, Germany, and Brainsway Inc., Jerusalem, Israel. The other authors have no conflicting interests related to this article to declare.

References

- Abraham WC, Tate WP. Metaplasticity: a new vista across the field of synaptic plasticity. *Prog Neurobiol* 1997;52:303–23.
- Ahdab R, Ayache SS, Farhat WH, Mylius V, Schmidt S, Brugières P, et al. Reappraisal of the anatomical landmarks of motor and premotor cortical regions for image-guided brain navigation in TMS practice. *Hum Brain Mapp* 2014;35:2435–47.
- Alm PA, Dreimanis K. Neuropathic pain: transcranial electric motor cortex stimulation using high frequency random noise. Case report of a novel treatment. *J Pain Res* 2013;6:479–686.
- Allman C, Amadi U, Winkler AM, Willkins L, Filippini N, Kischka U, et al. Ipsilesional anodal tDCS enhances the functional benefits of rehabilitation in patients after stroke. *Sci Transl Med* 2016;8:330re1.
- Amatachaya A, Auvichayapat N, Patjanasootorn N, Suphakunpinyo C, Ngernyam N, Aree-Uea B, et al. Effect of anodal transcranial direct current stimulation on autism: a randomized double-blind crossover trial. *Behav Neurol* 2014;2014:173073.
- Amatachaya A, Jensen MP, Patjanasootorn N, Auvichayapat N, Suphakunpinyo C, Janjarasjitt S, et al. The short-term effects of transcranial direct current stimulation on electroencephalography in children with autism: a randomized crossover controlled trial. *Behav Neurol* 2015;2015:928631.
- Ameli M, Grefkes C, Kemper F, Riegg FP, Rehme AK, Karbe H, et al. Differential effects of high-frequency repetitive transcranial magnetic stimulation over ipsilesional primary motor cortex in cortical and subcortical middle cerebral artery stroke. *Ann Neurol* 2009;66:298–309.
- Andrade C. Once- to twice-daily, 3-year domiciliary maintenance transcranial direct current stimulation for severe, disabling, clozapine-refractory continuous auditory hallucinations in schizophrenia. *J ECT* 2013;29:239–42.
- Angelakis E, Liouta E, Andreadis N, Leonardos A, Ktonas P, Stavrinou LC, et al. Transcranial alternating current stimulation reduces symptoms in intractable idiopathic cervical dystonia: a case study. *Neurosci Lett* 2013;533:39–43.
- Angelakis E, Liouta E, Andreadis N, Korfiatis S, Ktonas P, Stranjalis G, et al. Transcranial direct current stimulation effects in disorders of consciousness. *Arch Phys Med Rehabil* 2014;95:283–9.
- Antal A, Kincses TZ, Nitsche MA, Bartfai O, Paulus W. Excitability changes induced in the human primary visual cortex by transcranial direct current stimulation: direct electrophysiological evidence. *Invest Ophthalmol Vis Sci* 2004;45:702–7.
- Antal A, Terney D, Poreisz C, Paulus W. Towards unravelling task-related modulations of neuroplastic changes induced in the human motor cortex. *Eur J Neurosci* 2007;26:2687–91.
- Antal A, Boros K, Poreisz C, Chaieb L, Terney D, Paulus W. Comparatively weak after-effects of transcranial alternating current stimulation (tACS) on cortical excitability in humans. *Brain Stimul* 2008;1:97–105.
- Antal A, Terney D, Kuhn S, Paulus W. Anodal transcranial direct current stimulation of the motor cortex ameliorates chronic pain and reduces short intracortical inhibition. *J Pain Symptom Manage* 2010;39:890–903.
- Antal A, Kriener N, Lang N, Boros K, Paulus W. Cathodal transcranial direct current stimulation of the visual cortex in the prophylactic treatment of migraine. *Cephalalgia* 2011;31:820–8.
- Ardolino G, Bossi B, Barbieri S, Priori A. Non-synaptic mechanisms underlie the after-effects of cathodal transcutaneous direct current stimulation of the human brain. *J Physiol (London)* 2005;568:653–63.

- Assenza G, Campana C, Formica D, Schena E, Taffoni F, Di Pino G, et al. Efficacy of cathodal transcranial direct current stimulation in drug-resistant epilepsy: a proof of principle. *Conf Proc IEEE Eng Med Biol Soc* 2014;2014:530–3.
- Attal N, Ayache SS, Ciampi De Andrade D, Mhalla A, Baudic S, Jazat F, et al. Repetitive transcranial magnetic stimulation and transcranial direct current stimulation in neuropathic pain due to radiculopathy: a randomized sham controlled comparative study. *Pain* 2016;157:1224–31.
- Auvichayapat P, Janyacharoen T, Rotenberg A, Tiamkao S, Krisanaprakornkit T, Sinawat S, et al. Migraine prophylaxis by anodal transcranial direct current stimulation, a randomized, placebo-controlled trial. *J Med Assoc Thai* 2012;95:1003–12.
- Auvichayapat NN, Rotenberg A, Gersner R, Ngodklang S, Tiamkao S, Tassaneeyakul W, et al. Transcranial direct current stimulation for treatment of refractory childhood focal epilepsy. *Brain Stimul* 2013;6:696–700.
- Axelsson A, Ringdahl A. Tinnitus—a study of its prevalence and characteristics. *Br J Audiol* 1989;23:53–62.
- Ayache SS, Palm U, Chalah MA, Al-Ani T, Brignol A, Abdellaoui M, et al. Prefrontal tDCS Decreases Pain in Patients with Multiple Sclerosis. *Front Neurosci* 2016;10:147.
- Baker JM, Rorden C, Fridriksson J. Using transcranial direct-current stimulation to treat stroke patients with aphasia. *Stroke* 2010;41:1229–36.
- Basso A, Cattaneo S, Girelli L, Luzzatti C, Miozzo A, Modena L, et al. Treatment efficacy of language and calculation disorders and speech apraxia: a review of the literature. *Eur Phys Rehabil Med* 2011;47:101–21.
- Bation R, Poulet E, Haesebaert F, Saoud M, Brunelin J. Transcranial direct current stimulation in treatment-resistant obsessive-compulsive disorder: An open-label pilot study. *Prog Neuropsychopharmacol Biol Psychiatry* 2016;65:153–7.
- Batista EK, Klaus J, Fregni F, Nitsche MA, Nakamura-Palacios EM. A randomized placebo-controlled trial of targeted prefrontal cortex modulation with bilateral tDCS in patients with crack-cocaine dependence. *Int J Neuropsychopharmacol* 2015;18(12).
- Batsikadze G, Moliadze V, Paulus W, Kuo MF, Nitsche MA. Partially non-linear stimulation intensity-dependent effects of direct current stimulation on motor cortex excitability in humans. *J Physiol (London)* 2013;591:1987–2000.
- Belin P, Van Eeckhout P, Zilbovicius M, Remy P, François C, Guillaume S, et al. Recovery from nonfluent aphasia after melodic intonation therapy: a PET study. *Neurology* 1996;47:1504–11.
- Bennabi D, Nicolier M, Monnin J, Tio G, Pazart L, Vandell P, et al. Pilot study of feasibility of the effect of treatment with tDCS in patients suffering from treatment-resistant depression treated with escitalopram. *Clin Neurophysiol* 2015;126:1185–9.
- Benninger DH, Hallett M. Non-invasive brain stimulation for Parkinson's disease: current concepts and outlook 2015. *NeuroRehabilitation* 2015;37:11–24.
- Benninger DH, Lomarev M, Lopez G, Wassermann EM, Li X, Considine E, et al. Transcranial direct current stimulation for the treatment of parkinson's disease. *J Neurol Neurosurg Psychiatry* 2010;81:1105–11.
- Benninger DH, Lomarev M, Lopez G, Pal N, Luckenbaugh DA, Hallett M. Transcranial direct current stimulation for the treatment of focal hand dystonia. *Mov Disord* 2011;26:1698–702.
- Benninger DH, Sohn YH, Hallett M. Neuromodulation and transcranial magnetic stimulation. In: Daroff RB, Jankovic J, Mazziotta JC, Pomeroy SL, editors. *Bradley's neurology in clinical practice*. 7th ed. Amsterdam: Elsevier; 2015. chapter 36.
- Benussi A, Koch G, Cotelli M, Padovani A, Borroni B. Cerebellar transcranial direct current stimulation in patients with ataxia: a double-blind, randomized, sham-controlled study. *Mov Disord* 2015;30:1701–5.
- Berlim MT, Van den Eynde F, Daskalakis ZJ. Clinical utility of transcranial direct current stimulation (tDCS) for treating major depression: a systematic review and meta-analysis of randomized, double-blind and sham-controlled trials. *J Psychiatric Res* 2013;47:1–7.
- Bhanpuri NH, Bertuccio M, Young SJ, Lee AA, Sanger TD. Multiday Transcranial Direct Current Stimulation Causes Clinically Insignificant Changes in Childhood Dystonia: A Pilot Study. *J Child Neurol* 2015;30:1604–15.
- Bhogal SK, Teasell R, Speechley M. Intensity of aphasia therapy: Impact on recovery. *Stroke* 2003;34:987–99.
- Bienenstock EL, Cooper LN, Munro PW. Theory for the development of neuron selectivity: orientation specificity and binocular interaction in visual cortex. *J Neurosci* 1982;2:32–48.
- Bikson M, Inoue M, Akiyama H, Deans JK, Fox JE, Miyakawa H, et al. Effects of uniform extracellular DC electric fields on excitability in rat hippocampal slices in vitro. *J Physiol (London)* 2004;557:175–90.
- Bikson M, Rahman A, Datta A. Computational models of transcranial direct current stimulation. *Clin EEG Neurosci* 2012;43:176–83.
- Bikson M, Grossman P, Thomas C, Zannou AL, Jiang J, Adnan T, et al. Safety of transcranial direct current stimulation: evidence based update 2016. *Brain Stimul* 2016;9:641–61.
- Bindman LJ, Lippold OC, Redfearn JW. Long-lasting changes in the level of the electrical activity of the cerebral cortex produced by polarizing currents. *Nature* 1962;196:584–5.
- Bindman LJ, Lippold OC, Redfearn JW. The action of brief polarizing currents on the cerebral cortex of the rat (1) during current flow and (2) in the production of long-lasting after-effects. *J Physiol (London)* 1964;172:369–82.
- Blumberger DM, Tran LC, Fitzgerald PB, Hoy KE, Daskalakis ZJ. A randomized double-blind sham-controlled study of transcranial direct current stimulation for treatment-resistant major depression. *Front Psychiatry* 2012;3:74.
- Bocci T, Barloscio D, Vergari M, Di Rollo A, Rossi S, Priori A, et al. Spinal direct current stimulation modulates short intracortical inhibition. *Neuromodulation* 2015a;18:686–93.
- Bocci T, Caleo M, Vannini B, Vergari M, Cogiamanian F, Rossi S, et al. An unexpected target of spinal direct current stimulation: interhemispheric connectivity in humans. *J Neurosci Methods* 2015b;254:18–26.
- Bocci T, Marceglia S, Vergari M, Cognetto V, Cogiamanian F, Sartucci F, et al. Transcutaneous spinal direct current stimulation modulates human corticospinal system excitability. *J Neurophysiol* 2015c;114:440–6.
- Boehringer A, Macher K, Dukart J, Villringer A, Pleger B. Cerebellar transcranial direct current stimulation modulates verbal working memory. *Brain Stimul* 2012;6:649–53.
- Boggio PS, Ferrucci R, Rigonatti SP, Covre P, Nitsche M, Pascual-Leone A, et al. Effects of transcranial direct current stimulation on working memory in patients with Parkinson's disease. *J Neurol Sci* 2006;249:31–8.
- Boggio PS, Berman F, Vergara A, Muniz AL, Nahas FH, Leme PB, et al. Go-no-go task performance improvement after anodal transcranial direct DC stimulation of the left dorsolateral prefrontal cortex in major depression. *J Affect Disord* 2007;101:91–8.
- Boggio PS, Rigonatti SP, Ribeiro RB, Myczkowski ML, Nitsche MA, Pascual-Leone A, et al. A randomized, double-blind clinical trial on the efficacy of cortical direct current stimulation for the treatment of major depression. *Int J Neuropsychopharmacol* 2008a;11:249–54.
- Boggio PS, Sultani N, Fecteau S, Merabet L, Mecca T, Pascual-Leone A, et al. Prefrontal cortex modulation using transcranial DC stimulation reduces alcohol craving: a double-blind, sham-controlled study. *Drug Alcohol Depend* 2008b;92:55–60.
- Boggio PS, Khoury LP, Martins DC, Martins OE, de Macedo EC, Fregni F. Temporal cortex direct current stimulation enhances performance on a visual recognition memory task in Alzheimer disease. *J Neurol Neurosurg Psychiatry* 2009a;80:444–7.
- Boggio PS, Liguori P, Sultani N, Rezende L, Fecteau S, Fregni F. Cumulative priming effects of cortical stimulation on smoking cue-induced craving. *Neurosci Lett* 2009b;463:82–6.
- Boggio PS, Zaghi S, Villani AB, Fecteau S, Pascual-Leone A, Fregni F. Modulation of risk-taking in marijuana users by transcranial direct current stimulation (tDCS) of the dorsolateral prefrontal cortex (DLPFC). *Drug Alcohol Depend* 2010;112:220–5.
- Boggio PS, Ferrucci R, Mamei F, Martins D, Martins O, Vergari M, et al. Prolonged visual memory enhancement after direct current stimulation in Alzheimer's disease. *Brain Stimul* 2012;5:223–30.
- Borckardt JJ, Romagnuolo J, Reeves ST, Madan A, Frohman H, Beam W, et al. Feasibility, safety, and effectiveness of transcranial direct current stimulation for decreasing post-ERCP pain: a randomized, sham-controlled, pilot study. *Gastrointest Endosc* 2011;73:1158–64.
- Borckardt JJ, Reeves ST, Robinson SM, May JT, Epperson TI, Gunesman RJ, et al. Transcranial direct current stimulation (tDCS) reduces posturgical opioid consumption in total knee arthroplasty (TKA). *Clin J Pain* 2013;29:925–8.
- Bolognini N, Vallar G, Casati C, Latif LA, El-Nazer R, Williams J, et al. Neurophysiological and behavioral effects of tDCS combined with constraint-induced movement therapy in poststroke patients. *Neurorehabil Neural Repair* 2011;25:819–29.
- Bradnam LV, Stinear CM, Barber PA, Byblow WD. Contralesional hemisphere control of the proximal paretic upper limb following stroke. *Cereb Cortex* 2012;22:2662–71.
- Bradnam LV, Frasca J, Kimberley TJ. Direct current stimulation of primary motor cortex and cerebellum and botulinum toxin a injections in a person with cervical dystonia. *Brain Stimul* 2014;7:909–11.
- Bradnam LV, Graetz LJ, McDonnell MN, Ridding MC. Anodal transcranial direct current stimulation to the cerebellum improves handwriting and cyclic drawing kinematics in focal hand dystonia. *Front Hum Neurosci* 2015;9:286.
- Brady MC, Kelly H, Godwin G, Enderby P. Speech and language therapy for aphasia following stroke (review). *Cochrane Database Syst Rev* 2012;5:CD000425.
- Brainin M, Barnes M, Baron JC, Gilhus NE, Hughes R, Selmaj K, et al. Guidance for the preparation of neurological management guidelines by EFNS scientific task forces—revised recommendations 2004. *Eur J Neurol* 2004;11:577–81.
- Brem AK, Fried PJ, Horvath JC, Robertson EM, Pascual-Leone A. Is neuroenhancement by noninvasive brain stimulation a net zero-sum proposition? *Neuroimage* 2014;85:1058–68.
- Brittain JS, Probert-Smith P, Aziz TZ, Brown P. Tremor suppression by rhythmic transcranial current stimulation. *Curr Biol* 2013;23:436–40.
- Brunelin J, Mondino M, Gassab L, Haesebaert F, Gaha L, Suaud-Chagny MF, et al. Examining transcranial directcurrent stimulation (tDCS) as a treatment for hallucinations in schizophrenia. *Am J Psychiatry* 2012a;169:719–24.
- Brunelin J, Mondino M, Haesebaert F, Saoud M, Suaud-Chagny MF, Poulet E. Efficacy and safety of bifocal tDCS as an interventional treatment for refractory schizophrenia. *Brain Stimul* 2012b;5:431–2.
- Brunoni AR, Amadera J, Berbel B, Volz MS, Rizzerio BG, Fregni F. A systematic review on reporting and assessment of adverse effects associated with transcranial direct current stimulation. *Int J Neuropsychopharmacol* 2011;14:1133–45.
- Brunoni AR, Ferrucci R, Fregni F, Boggio PS, Priori A. Transcranial direct current stimulation for the treatment of major depressive disorder: a summary of preclinical, clinical and translational findings. *Prog Neuropsychopharmacol Biol Psychiatry* 2012;39:9–16.
- Brunoni AR, Ferrucci R, Bortolomasi M, Scelzo E, Boggio PS, Fregni F, et al. Interactions between transcranial direct current stimulation (tDCS) and

- pharmacological interventions in the Major Depressive Episode: findings from a naturalistic study. *Eur Psychiatry* 2013a;28:356–61.
- Brunoni AR, Valiengo L, Baccaro A, Zanao TA, de Oliveira JF, Goulart A, et al. The sertraline vs. electrical current therapy for treating depression clinical study: results from a factorial, randomized, controlled trial. *JAMA Psychiatry* 2013b;70:383–91.
- Brunoni AR, Zanao TA, Ferrucci R, Priori A, Valiengo L, de Oliveira JF, et al. Bifrontal tDCS prevents implicit learning acquisition in antidepressant-free patients with major depressive disorder. *Prog Neuropsychopharmacol Biol Psychiatry* 2013c;43:146–50.
- Brunoni AR, Boggio PS, De Raedt R, Benseñor IM, Lotufo PA, Namur V, et al. Cognitive control therapy and transcranial direct current stimulation for depression: a randomized, double-blinded, controlled trial. *J Affect Disord* 2014a;162:43–9.
- Brunoni AR, Júnior RF, Kemp AH, Lotufo PA, Benseñor IM, Fregni F. Differential improvement in depressive symptoms for tDCS alone and combined with pharmacotherapy: an exploratory analysis from the sertraline vs. electrical current therapy for treating depression clinical study. *Int J Neuropsychopharmacol* 2014b;17:53–61.
- Brunoni AR, Shiozawa P, Truong D, Javitt DC, Elks H, Fregni F, et al. Understanding tDCS effects in schizophrenia: a systematic review of clinical data and an integrated computation modeling analysis. *Expert Rev Med Devices* 2014c;11:383–94.
- Brunoni AR, Zanao ZA, Vanderhasselt MA, Valiengo L, de Oliveira JF, Boggio PS, et al. Enhancement of affective processing induced by bifrontal transcranial direct current stimulation in patients with major depression. *Neuromodulation* 2014d;17:138–42.
- Brunoni AR, Moffa AH, Fregni F, Palm U, Padberg F, Blumberger DM, et al. Transcranial direct current stimulation for the acute major depressive episode: a meta-analysis of individual patient data. *Br J Psychiatry* 2016a;208:522–31.
- Brunoni AR, Tortella G, Benseñor IM, Lotufo PA, Carvalho AF, Fregni F. Cognitive effects of transcranial direct current stimulation in depression: results from the SELECT-TDCS trial and insights for further clinical trials. *J Affect Disord* 2016b;202:46–52.
- Buono VF, Brunoni AR, Boggio PS, Benseñor IM, Fregni F. Mood and cognitive effects of transcranial direct current stimulation in post-stroke depression. *Neurocase* 2011;17:318–22.
- Butler AJ, Shuster M, O'Hara E, Hurley K, Middlebrooks D, Guilkey K. A meta-analysis of the efficacy of anodal transcranial direct current stimulation for upper limb motor recovery in stroke survivors. *J Hand Ther* 2013;26:162–71.
- Buttkus F, Weidenmüller M, Schneider S, Jabusch HC, Nitsche MA, Paulus W, et al. Failure of cathodal direct current stimulation to improve fine motor control in musician's dystonia. *Mov Disord* 2010;25:389–94.
- Buttkus F, Baur V, Jabusch HC, de la Cruz Gomez-Pellin M, Paulus W, Nitsche MA, et al. Single-session tDCS-supported retraining does not improve fine motor control in musician's dystonia. *Restor Neurol Neurosci* 2011;29:85–90.
- Bystad M, Grønli O, Rasmussen ID, Gundersen N, Nordvang L, Wang-Iversen H, et al. Transcranial direct current stimulation as a memory enhancer in patients with Alzheimer's disease: a randomized, placebo-controlled trial. *Alzheimers Res Ther* 2016;8(1):13.
- Cabrera LY, Evans EL, Hamilton RH. Ethics of the electrified mind: defining issues and perspectives on the principled use of brain stimulation in medical research and clinical care. *Brain Topogr* 2014;27:33–45.
- Campana S, Caltagirone C, Marangolo P. Combining voxel-based lesion-symptom mapping (VLSM) with A-tDCS language treatment: predicting outcome of recovery in nonfluent chronic aphasia. *Brain Stimul* 2015;8:769–76.
- Campbell S, Mariott M, Nahmias C, McQueen GM. Lower hippocampal volume in patients suffering from depression: a meta-analysis. *Am J Psychiatry* 2004;161:598–607.
- Caramia MD, Palmieri MG, Giacomini P, Iani C, Dally L, Silvestrini M. Ipsilateral activation of the unaffected motor cortex in patients with hemiparetic stroke. *Clin Neurophysiol* 2000;111:1990–6.
- Castillo-Saavedra L, Gebodh N, Bikson M, Diaz-Cruz C, Brandao R, Coutinho L, et al. Clinically effective treatment of fibromyalgia pain with high-definition transcranial direct current stimulation: phase II open-label dose optimization. *J Pain* 2016;17:14–26.
- Cha HK, Ji SG, Kim MK, Chang JS. Effect of transcranial direct current stimulation of function in patients with stroke. *J Phys Ther Sci* 2014;26:363–5.
- Chaieb L, Antal A, Paulus W. Transcranial alternating current stimulation in the low kHz range increases motor cortex excitability. *Restor Neurol Neurosci* 2011;29:167–75.
- Chalah MA, Riachi N, Ahdab R, Créange A, Lefaucheur JP, Ayache SS. Fatigue in multiple sclerosis: neural correlates and the role of non-invasive brain stimulation. *Front Cell Neurosci* 2015;9:460.
- Chang MC, Kim DY, Park DH. Enhancement of cortical excitability and lower limb motor function in patients with stroke by transcranial direct current stimulation. *Brain Stimul* 2015;8:561–6.
- Charvet LE, Kasschau M, Datta A, Knotkova H, Stevens MC, Alonzo A, et al. Remotely-supervised transcranial direct current stimulation (tDCS) for clinical trials: guidelines for technology and protocols. *Front Syst Neurosci* 2015;9:26.
- Chen JC, Hammerer D, D'Ostilio K, Casula EP, Marshall L, Tsai CH, et al. Bi-directional modulation of somatosensory mismatch negativity with transcranial direct current stimulation: an event related potential study. *J Physiol (London)* 2014;592:745–57.
- Cherney LR, Babbitt EM, Hurwitz R, Rogers LM, Stinear J, Wang X, et al. Transcranial direct current stimulation and aphasia: the case of Mr. C. *Top Stroke Rehabil* 2013;20:5–21.
- Chhatbar PY, Ramakrishnan V, Kautz S, George MS, Adams RJ, Feng W. Transcranial direct current stimulation post-stroke upper extremity motor recovery studies exhibit a dose-response relationship. *Brain Stimul* 2016;9:16–26.
- Cho HJ, Hallett M. Non-invasive brain stimulation for treatment of focal hand dystonia: update and future direction. *J Mov Disord* 2016;9:55–62.
- Cipollari S, Veniero D, Razzano C, Caltagirone C, Koch G, Marangolo P. Combining TMS-EEG with transcranial direct current stimulation language treatment in aphasia. *Expert Rev Neurother* 2015;15:833–45.
- Claes L, Stamberger H, Van de Heyning P, De Ridder D, Vanneste S. Auditory cortex tACS and tRNS for tinnitus: single versus multiple sessions. *Neural Plast* 2014;2014:436713.
- Code C, Petheram B. Delivering for aphasia. *Int J Speech Lang Pathol* 2011;13:3–10.
- Coffman BA, Clark VP, Parasuraman R. Battery powered thought: enhancement of attention, learning, and memory in healthy adults using transcranial direct current stimulation. *Neuroimage* 2014;85:895–908.
- Cogiமானியன் F, Vergari M, Pulecchi F, Marceglia S, Priori A. Effect of spinal transcutaneous direct current stimulation on somatosensory evoked potentials in humans. *Clin Neurophysiol* 2008;119:2636–40.
- Cogiமானியன் F, Vergari M, Schiaffini E, Marceglia S, Ardolino G, Barbieri S, et al. Transcutaneous spinal cord direct current stimulation inhibits the lower limb nociceptive flexion reflex in human beings. *Pain* 2011;152:370–5.
- Cogiமானியன் F, Ardolino G, Vergari M, Ferrucci R, Ciocca M, Scelzo E, et al. Transcutaneous spinal direct current stimulation. *Front Psychiatry* 2012;3:63.
- Cohen Kadosh R, Levy N, O'Shea J, Shea N, Savulescu J. The neuroethics of non-invasive brain stimulation. *Curr Biol* 2012;22:R108–11.
- Conti CL, Nakamura-Palacios EM. Bilateral transcranial direct current stimulation over dorsolateral prefrontal cortex changes the drug-cued reactivity in the anterior cingulate cortex of crack-cocaine addicts. *Brain Stimul* 2014;7:130–2.
- Cosmo C, Baptista AF, de Araújo AN, do Rosário RS, Miranda JG, Montoya P, et al. A randomized, double-blind, sham-controlled trial of transcranial direct current stimulation in attention-deficit/hyperactivity disorder. *PLoS One* 2015;10:e0135371.
- Costa-Ribeiro A, Maux A, Bosford T, Aoki Y, Castro R, Baltar A, et al. Transcranial direct current stimulation associated with gait training in Parkinson's disease: a pilot randomized clinical trial. *Dev Neurorehabil* 2016. <http://dx.doi.org/10.3109/17518423.2015.1131755>, in press.
- Costa-Ribeiro A, Maux A, Bosford T, Tenório Y, Marques D, Carneiro D, et al. Dopamine-dependent effects of combining transcranial direct current stimulation with gait training on cortical excitability and functional mobility in Parkinson's Disease. *J Rehabil Med* 2016b;48:819–23.
- Cotelli M, Manenti R, Brambilla M, Petesi M, Rosini S, Ferrari C, et al. Anodal tDCS during face-name associations memory training in Alzheimer's patients. *Front Aging Neurosci* 2014a;6:38.
- Cotelli M, Manenti R, Petesi M, Brambilla M, Cosseddu M, Zanetti O, et al. Treatment of primary progressive aphasia by transcranial direct current stimulation combined with language training. *J Alzheimers Dis* 2014b;39:799–808.
- Cramer SC, Nelles G, Benson RR, Kaplan JD, Parker RA, Kwong KK, et al. A functional MRI study of subjects recovered from hemiparetic stroke. *Stroke* 1997;28:2518–27.
- Cummiford CM, Nascimento TD, Foerster BR, Clauw DJ, Zubieta JK, Harris RE, et al. Changes in resting state functional connectivity after repetitive transcranial direct current stimulation applied to motor cortex in fibromyalgia patients. *Arthritis Res Ther* 2016;18:40.
- Cunningham DA, Varnerin N, Machado A, Bonnett C, Janini D, Roelle S, et al. Stimulation targeting higher motor areas in stroke rehabilitation: A proof-of-concept, randomized, double-blinded placebo-controlled study of effectiveness and underlying mechanisms. *Restor Neurol Neurosci* 2015;33:911–26.
- Cuyppers K, Leenus DJ, Van Wijmeersch B, Thijs H, Levin O, Swinnen SP, et al. Anodal tDCS increases corticospinal output and projection strength in multiple sclerosis. *Neurosci Lett* 2013;554:151–5.
- da Silva MC, Conti CL, Klaus J, Alves LG, do Nascimento Cavalcante HM, Fregni F, et al. Behavioral effects of transcranial direct current stimulation (tDCS) induced dorsolateral prefrontal cortex plasticity in alcohol dependence. *J Physiol (Paris)* 2013;107:493–502.
- Dasilva AF, Mendonca ME, Zaghi S, Lopes M, Dossantos MF, Spierings EL, et al. TDCS-induced analgesia and electrical fields in pain-related neural networks in chronic migraine. *Headache* 2012;52:1283–95.
- Datta A, Truong D, Minhas P, Parra LC, Bikson M. Inter-individual variation during transcranial direct current stimulation and normalization of dose using MRI-derived computational models. *Front Psychiatry* 2012;3:91.
- De Ridder D, Vanneste S, Weisz N, Londero A, Schlee W, Elgoyhen AB, et al. An integrative model of auditory phantom perception: tinnitus as a unified percept of interacting separable subnetworks. *Neurosci Biobehav Rev* 2014;44:16–32.
- Debener S, Beauducel A, Nessler D, Brocke B, Heilemann H, Kayser J. Is the resting anterior EEG alpha asymmetry a trait marker for depression? Findings for healthy adults and clinically depressed patients. *Neuropsychobiology* 2000;41:31–7.
- Dell'Osso B, Dobrea C, Arici C, Benatti B, Ferrucci R, Vergari M, et al. Augmentative transcranial direct current stimulation (tDCS) in poor responder depressed patients: a follow-up study. *CNS Spectr* 2013;20:1–8.
- den Uyl TE, Gladwin TE, Wiers RW. Transcranial direct current stimulation, implicit alcohol associations and craving. *Biol Psychol* 2015;105:37–42.
- Di Pino G, Pellegrino G, Assenza G, Capone F, Ferreri F, Formica D, et al. Modulation of brain plasticity in stroke: a novel model for neurorehabilitation. *Nat Rev Neurosci* 2014;10:597–608.

- Doeltgen SH, Bradnam LV, Young JA, Fong E. Transcranial non-invasive brain stimulation in swallowing rehabilitation following stroke—a review of the literature. *Physiol Behav* 2015;143:1–9.
- Donnell A, D Nascimento T, Lawrence M, Gupta V, Zieba T, Truong DQ, et al. High-definition and non-invasive brain modulation of pain and motor dysfunction in chronic TMD. *Brain Stimul* 2015;8:1085–92.
- Doruk D, Gray Z, Bravo GL, Pascual-Leone A, Fregni F. Effects of tDCS on executive function in Parkinson's disease. *Neurosci Lett* 2014;582:27–31.
- Dubois PE, Ossemann M, de Fays K, De Bue P, Gourdin M, Jamart J, et al. Postoperative analgesic effect of transcranial direct current stimulation in lumbar spine surgery: a randomized control trial. *Clin J Pain* 2013;29:696–701.
- Dutta A, Paulus W, Nitsche MA. Facilitating myoelectric-control with transcranial direct current stimulation: a preliminary study in healthy humans. *J Neuroeng Rehabil* 2014;11:13.
- Dymond AM, Cogger RW, Serafetinides EA. Intracerebral current levels in man during electroless therapy. *Biol Psychiatry* 1975;10:101–4.
- Easterbrook PJ, Berlin JA, Gopalan R, Matthews DR. Publication bias in clinical research. *Lancet* 1991;337:867–72.
- Eggers C, Grüner U, Ameli M, Sarfeld AS, Nowak DA. 1 Hz rTMS preconditioned by tDCS over the primary motor cortex in Parkinson's disease: absence of effect on arm lift and hand grip force control. *Motor Control* 2012;16:284–92.
- Elgoyhen AB, Langguth B, De Ridder D, Vanneste S. Tinnitus: perspectives from human neuroimaging. *Nat Rev Neurosci* 2015;16:632–42.
- Elsner B, Kugler J, Pohl M, Mehrholz J. Transcranial direct current stimulation (tDCS) for improving aphasia in patients after stroke. *Cochrane Database Syst Rev* 2013(6):CD009760.
- Elsner B, Kugler J, Pohl M, Mehrholz J. Transcranial direct current stimulation (tDCS) for improving function and activities of daily living in patients after stroke. *Cochrane Database Syst Rev* 2013(11):CD009645.
- Elsner B, Kugler J, Pohl M, Mehrholz J. Transcranial direct current stimulation (tDCS) for improving aphasia in patients with aphasia after stroke. *Cochrane Database Syst Rev* 2015(5):CD009760.
- Elsner B, Kugler J, Pohl M, Mehrholz J. Transcranial direct current stimulation for improving spasticity after stroke: a systematic review with meta-analysis. *J Rehabil Med* 2016a;48:565–70.
- Elsner B, Kugler J, Pohl M, Mehrholz J. Transcranial direct current stimulation (tDCS) for idiopathic Parkinson's disease. *Cochrane Database Syst Rev* 2016b;7:CD010916.
- Elsner B, Kugler J, Pohl M, Mehrholz J. Transcranial direct current stimulation (tDCS) for improving activities of daily living, and physical and cognitive functioning, in people after stroke. *Cochrane Database Syst Rev* 2016c;3:CD009645.
- Faber M, Vanneste S, Fregni F, De Ridder D. Top down prefrontal affective modulation of tinnitus with multiple sessions of tDCS of dorsolateral prefrontal cortex. *Brain Stimul* 2012;5:492–8.
- Fagerlund AJ, Hansen OA, Aslaksen PM. Transcranial direct current stimulation as a treatment for patients with fibromyalgia: a randomized controlled trial. *Pain* 2015;156:62–71.
- Falcone M, Bernardo L, Ashare RL, Hamilton R, Faseyitan O, McKee SA, et al. Transcranial direct current brain stimulation increases ability to resist Smoking. *Brain Stimul* 2016;9:191–6.
- Fant RV, Buchhalter AL, Buchman AC, Henningfield JE. Pharmacotherapy for tobacco dependence. *Handb Exp Pharmacol* 2009;192:487–510.
- Faria P, Hallett M, Miranda PC. A finite element analysis of the effect of electrode area and inter-electrode distance on the spatial distribution of the current density in tDCS. *J Neural Eng* 2011;8:066017.
- Fecteau S, Agosta S, Hone-Blanchet A, Fregni F, Boggio P, Ciraulo D, et al. Modulation of smoking and decision-making behaviors with transcranial direct current stimulation in tobacco smokers: a preliminary study. *Drug Alcohol Depend* 2014;140:78–84.
- Fehlings MG, Tator CH. The effect of direct current field polarity on recovery after acute experimental spinal cord injury. *Brain Res* 1992;579:32–42.
- Ferrucci R, Priori A. Transcranial cerebellar direct current stimulation (cerebellar tDCS): Motor control, cognition, learning and emotions. *NeuroImage* 2013;85:918–23.
- Ferrucci R, Mameli F, Guidi I, Mrakic-Spota S, Vergari M, Marceglia S, et al. Transcranial direct current stimulation improves recognition memory in Alzheimer disease. *Neurology* 2008a;71:493–8.
- Ferrucci R, Marceglia S, Vergari M, Cogiamanian F, Mrakic-Spota S, Mameli F, et al. Cerebellar transcranial direct current stimulation impairs the practice-dependent proficiency increase in working memory. *J Cogn Neurosci* 2008b;20:1687–97.
- Ferruci R, Bortolomasi M, Brunoni AR, Vergari M, Tadini L, Giacomuzzi M, et al. Comparative benefits of transcranial direct current stimulation (tDCS) treatment in patients with mild/moderate vs. severe depression. *Clin Neuropsychiatry* 2009;6:246–51.
- Ferrucci R, Giannicola G, Rosa M, Fumagalli M, Boggio PS, Hallett M, et al. Cerebellum and processing of negative facial emotions: cerebellar transcranial DC stimulation specifically enhances the emotional recognition of facial anger and sadness. *Cogn Emot* 2012;26:786–99.
- Ferrucci R, Brunoni AR, Parazzini M, Vergari M, Rossi E, Fumagalli M, et al. Modulating human procedural learning by cerebellar transcranial direct current stimulation. *Cerebellum* 2013;12:485–92.
- Ferrucci R, Vergari M, Cogiamanian F, Bocci T, Ciocca M, Tomasini E, et al. Transcranial direct current stimulation (tDCS) for fatigue in multiple sclerosis. *NeuroRehabilitation* 2014;34:121–7.
- Ferrucci R, Cortese F, Priori A. Cerebellar tDCS: how to do it. *Cerebellum* 2015;14:27–30.
- Ferrucci R, Cortese F, Bianchi M, Pittera D, Turrone R, Bocci T, et al. Cerebellar and motor cortical transcranial stimulation decrease levodopa-induced Dyskinesias in Parkinson's disease. *Cerebellum* 2016;15:43–7.
- Feurra M, Pasqualetti P, Bianco G, Santarnecchi E, Rossi A, Rossi S. State-dependent effects of transcranial oscillatory currents on the motor system: what you think matters. *J Neurosci* 2013;33:17483–9.
- Fiori V, Coccia M, Marinelli CV, Vecchi V, Bonifazi S, Ceravolo MG, et al. Transcranial direct current stimulation improves word retrieval in healthy and nonfluent aphasic subjects. *J Cogn Neurosci* 2011;23:2309–23.
- Fiori V, Cipollari S, Di Paola M, Razzano C, Caltagirone C, Marangolo P. TDCS stimulation segregates words in the brain: evidence from aphasia. *Front Hum Neurosci* 2013;7:269.
- Fitz NS, Reiner PB. The challenge of crafting policy for do-it-yourself brain stimulation. *J Med Ethics* 2015;41:410–2.
- Fitzgerald PB, McQueen S, Daskalakis ZJ, Hoy KE. A negative pilot study of daily bimodal transcranial direct current stimulation in schizophrenia. *Brain Stimul* 2014;7:813–6.
- Flöel A, Meinzer M, Kirstein R, Nijhof S, Deppe M, Knecht S, et al. Short-term anomia training and electrical brain stimulation. *Stroke* 2011;42:2065–7.
- Foerster BR, Nascimento TD, DeBoer M, Bender MA, Rice IC, Truong DQ, et al. Excitatory and inhibitory brain metabolites as targets of motor cortex transcranial direct current stimulation therapy and predictors of its efficacy in fibromyalgia. *Arthritis Rheumatol* 2015;67:576–81.
- Forogh B, Mirshaki Z, Raissi GR, Shirazi A, Mansoori K, Ahadi T. Repeated sessions of transcranial direct current stimulation for treatment of chronic subjective tinnitus: a pilot randomized controlled trial. *Neuro Sci* 2016;37:253–9.
- Francis JT, Gluckman BJ, Schiff SJ. Sensitivity of neurons to weak electric fields. *J Neurosci* 2003;23:7255–61.
- Frank E, Schecklmann M, Landgrebe M, Burger J, Kreuzer P, Poepl TB, et al. Treatment of chronic tinnitus with repeated sessions of prefrontal transcranial direct current stimulation: outcomes from an open-label pilot study. *J Neuro* 2012;259:327–33.
- Fregni F, Boggio PS, Lima MC, Ferreira MJ, Wagner T, Rigonatti SP, et al. A sham-controlled, phase II trial of transcranial direct current stimulation for the treatment of central pain in traumatic spinal cord injury. *Pain* 2006a;122:197–209.
- Fregni F, Boggio PS, Nitsche MA, Rigonatti SP, Pascual-Leone A. Cognitive effects of repeated sessions of transcranial direct current stimulation in patients with depression. *Depr Anxiety* 2006b;23:1–3.
- Fregni F, Boggio PS, Nitsche MA, Marcolin MA, Rigonatti SP, Pascual-Leone A. Treatment of major depression with transcranial direct current stimulation. *Bipolar Disord* 2006c;8:203–5.
- Fregni F, Boggio PS, Santos MC, Lima M, Vieira AL, Rigonatti SP, et al. Noninvasive cortical stimulation with transcranial direct current stimulation in Parkinson's disease. *Mov Disord* 2006d;21:1693–702.
- Fregni F, Gimenes R, Valle AC, Ferreira MJ, Rocha RR, Natalle L, et al. A randomized, sham-controlled, proof of principle study of transcranial direct current stimulation for the treatment of pain in fibromyalgia. *Arthritis Rheum* 2006e;54:3988–98.
- Fregni F, Marcondes R, Boggio PS, Marcolin MA, Rigonatti SP, Sanchez TG, et al. Transient tinnitus suppression induced by repetitive transcranial magnetic stimulation and transcranial direct current stimulation. *Eur J Neurol* 2006f;13:996–1001.
- Fregni F, Thome-Souza S, Nitsche MA, Freedman SD, Valente KD, Pascual-Leone A. A controlled clinical trial of cathodal DC polarization in patients with refractory epilepsy. *Epilepsia* 2006g;47:335–42.
- Fresnoza S, Paulus W, Nitsche MA, Kuo MF. Nonlinear dose-dependent impact of D1 receptor activation on motor cortex plasticity in humans. *J Neurosci* 2014;34:2744–53.
- Frey ME, Manchikanti L, Benyamin RM, Schultz DM, Smith HS, Cohen SP. Spinal cord stimulation for patients with failed back surgery syndrome: a systematic review. *Pain Physician* 2009;12:379–97.
- Fridriksson J, Richardson JD, Baker JM, Rorden C. Transcranial direct current stimulation improves naming reaction time in fluent aphasia: a double-blind, sham-controlled study. *Stroke* 2011;42:819–21.
- Fröhlich F, Burrello TN, Mellin JM, Cordle AL, Lustenberger CM, Gilmore JH, Jarskog LF. Exploratory study of once-daily transcranial direct current stimulation (tDCS) as a treatment for auditory hallucinations in schizophrenia. *Eur Psychiatry* 2016;33:54–60.
- Furuya S, Nitsche MA, Paulus W, Altenmüller E. Surmounting retraining limits in musicians' dystonia by transcranial stimulation. *Ann Neurol* 2014;75:700–7.
- Galea JM, Jayaram G, Ajagbe L, Celnik P. Modulation of cerebellar excitability by polarity-specific noninvasive direct current stimulation. *J Neurosci* 2009;29:9115–22.
- Galea JM, Vazquez A, Pasricha N, de Vivry JJ, Celnik P. Dissociating the roles of the cerebellum and motor cortex during adaptive learning: the motor cortex retains what the cerebellum learns. *Cereb Cortex* 2012;21:1761–70.
- Galletta EE, Cancelli A, Cottone C, Simonelli I, Tecchio F, Bikson M, et al. Use of computational modeling to inform tDCS electrode montages for the promotion of language recovery in post-stroke Aphasia. *Brain Stimul* 2015;8:1108–15.
- Gallus S, Lugo A, Garavello W, Bosetti C, Santoro E, Colombo P, et al. Prevalence and determinants of tinnitus in the Italian adult population. *Neuroepidemiology* 2015;45:12–9.

- Garin P, Gilain C, Van Damme JP, de Fays K, Jamart J, Ossemann M, et al. Short- and long-lasting tinnitus relief induced by transcranial direct current stimulation. *J Neurol* 2011;258:1940–8.
- Geroin C, Picelli A, Munari D, Waldner A, Tomelleri C, Smiana N. Combined transcranial direct current stimulation and robot-assisted gait training in patients with chronic stroke: a preliminary comparison. *Clin Rehabil* 2011;25:537–48.
- Gironell A, Martínez-Horta S, Aguilar S, Torres V, Pagonabarraga J, Pascual-Sedano B, et al. Transcranial direct current stimulation of the cerebellum in essential tremor: a controlled study. *Brain Stimul* 2014;7:491–2.
- Glaser J, Reeves ST, Stoll WD, Epperson TI, Hilbert M, Madan A, et al. Motor/prefrontal transcranial direct current stimulation (tDCS) following lumbar surgery reduces postoperative analgesia use. *Spine (Phila Pa 1976)* 2016;41:835–9.
- Gluckman BJ, Neel EJ, Netoff TI, Ditto WL, Spano ML, Schiff SJ. Electric field suppression of epileptiform activity in hippocampal slices. *J Neurophysiol* 1996;76:4202–5.
- Goldstein RZ, Volkow ND. Drug addiction and its underlying neuro-biological basis: neuroimaging evidence for the involvement of the frontal cortex. *Am J Psychiatry* 2002;159:1642–52.
- Gomes JS, Shiozawa P, Dias AM, Valverde Ducos D, Akiba H, Trevizol AP, et al. Left dorsolateral prefrontal cortex anodal tDCS effects on negative symptoms in schizophrenia. *Brain Stimul* 2015;8:989–91.
- Gorini A, Lucchiari C, Russell-Edu W, Pravettoni G. Modulation of risky choices in recently abstinent dependent cocaine users: a transcranial direct-current stimulation study. *Front Hum Neurosci* 2014;8:661.
- Gorman AL. Differential patterns of activation of the pyramidal system elicited by surface anodal and cathodal cortical stimulation. *J Neurophysiol* 1966;29:547–64.
- Grabow TS, Tella PK, Raja S. Spinal cord stimulation for complex regional pain syndrome: an evidence-based medicine review of the literature. *Clin J Pain* 2003;19:371–83.
- Grefkes C, Ward NS. Cortical reorganization after stroke: how much and how functional? *Neuroscientist* 2014;20:56–70.
- Grimaldi G, Manto M. Anodal transcranial direct current stimulation (tDCS) decreases the amplitudes of long-latency stretch reflexes in cerebellar ataxia. *Ann Biomed Eng* 2013;41:2437–47.
- Grimaldi G, Argyropoulos GP, Boehringer A, Celnik P, Edwards MJ, Ferrucci R, et al. Non-invasive cerebellar stimulation—a consensus paper. *Cerebellum* 2014a;13:121–38.
- Grimaldi G, Oulad Ben Taib N, Manto M, Bodranghien F. Marked reduction of cerebellar deficits in upper limbs following transcranial cerebello-cerebral DC stimulation: tremor reduction and re-programming of the timing of antagonist commands. *Front Syst Neurosci* 2014b;8:9.
- Grimaldi G, Argyropoulos GP, Bastian A, Cortes M, Davis NJ, Edwards DJ, et al. Cerebellar transcranial direct current stimulation (ctDCS): a novel approach to understanding cerebellar function in health and disease. *Neuroscientist* 2016;22:83–97.
- Grüner U, Eggert C, Ameli M, Sarfeld AS, Fink GR, Nowak DA. 1 Hz rTMS preconditioned by tDCS over the primary motor cortex in Parkinson's disease: effects on bradykinesia of arm and hand. *J Neural Transm* 2010;117:207–16.
- Guleyupoglu B, Schestatsky P, Edwards D, Fregni F, Bikson M. Classification of methods in transcranial electrical stimulation (tES) and evolving strategy from historical approaches to contemporary innovations. *J Neurosci Methods* 2013;219:297–311.
- Haesebaert F, Mondino M, Saoud M, Poulet E, Brunelin J. Efficacy and safety of fronto-temporal transcranial random noise stimulation (tRNS) in drug-free patients with schizophrenia: a case study. *Schizophr Res* 2014;159:251–2.
- Hagenacker T, Bude V, Naegel S, Holle D, Katsarava Z, Diener HC, et al. Patient-conducted anodal transcranial direct current stimulation of the motor cortex alleviates pain in trigeminal neuralgia. *J Headache Pain* 2014;15:78.
- Hamada M, Strigaro G, Murase N, Sadnicka A, Galea JM, Edwards MJ, et al. Cerebellar modulation of human associative plasticity. *J Physiol (London)* 2012;590:2365–74.
- Hamada M, Murase N, Hasan A, Balaratnam M, Rothwell JC. The role of interneuron networks in driving human motor cortical plasticity. *Cereb Cortex* 2013;23:1593–605.
- Hamilton JP, Siemer M, Gottlib IH. Amygdala volume in major depressive disorder: a meta-analysis of magnetic resonance imaging studies. *Mol Psychiatry* 2008;13:993–1000.
- Hamilton R, Messing S, Chatterjee A. Rethinking the thinking cap: ethics of neural enhancement using noninvasive brain stimulation. *Neurology* 2011;76:187–93.
- Hardwick RM, Celnik PA. Cerebellar direct current stimulation enhances motor learning in older adults. *Neurobiol Aging* 2014;35:2217–21.
- Harvey RL, Winstein CJ. Everest Trial Group. Design for the everest randomized trial of cortical stimulation and rehabilitation for arm function following stroke. *Neurorehabil Neural Repair* 2009;23:32–44.
- Heide AC, Winkler T, Helms HJ, Nitsche MA, Trenkwalder C, Paulus W, et al. Effects of transcutaneous spinal direct current stimulation in idiopathic restless legs patients. *Brain Stimul* 2014;7:636–42.
- Heinrichs JH. The promises and perils of non-invasive brain stimulation. *Int J Law Psychiatry* 2012;35:121–9.
- Heinz A, Beck A, Grusser M, Grace AA, Wrase J. Identifying the neural circuitry of alcohol craving and relapse vulnerability. *Addict Biol* 2009;14:108–18.
- Heller AJ. Classification and epidemiology of tinnitus. *Otolaryngol Clin North Am* 2003;36:239–48.
- Heneka MT, Carson MJ, El Khoury J, Landreth GE, Brosseron F, Feinstein DL, et al. Neuroinflammation in Alzheimer's disease. *Lancet Neurol* 2015;14:388–405.
- Herzfeld DJ, Pastor D, Haith AM, Rossetti Y, Shadmehr R, O'Shea J. Contributions of the cerebellum and the motor cortex to acquisition and retention of motor memories. *NeuroImage* 2014;98:147–58.
- Hesse S, Waldner A, Mehrholz J, Tomelleri C, Pohl M, Werner C. Combined transcranial direct current stimulation and robot-assisted arm training in subacute stroke patients: an exploratory, randomized multicenter trial. *Neurorehabil Neural Repair* 2011;25:838–46.
- Hill AT, Fitzgerald PB, Hoy KE. Effects of anodal transcranial direct current stimulation on working memory: a systematic review and meta-analysis of findings from healthy and neuropsychiatric populations. *Brain Stimul* 2016;9:197–208.
- Ho KA, Bai S, Martin D, Alonzo A, Dokos S, Puras P, et al. A pilot study of alternative transcranial direct current stimulation electrode montages for the treatment of major depression. *J Affect Disord* 2014;167:251–8.
- Hodaj H, Payen JF, Lefaucheur JP. A case of long-term treatment of chronic pain syndrome by anodal tDCS of the motor cortex, previously resistant to high-frequency rTMS and implanted spinal cord stimulation. *Brain Stimul* 2016;9:618–20.
- Holsheimer J, Lefaucheur JP, Buitenweg JR, Goujon C, Nineb A, Nguyen JP. The role of intra-operative motor evoked potentials in the optimization of chronic cortical stimulation for the treatment of neuropathic pain. *Clin Neurophysiol* 2007a;118:2287–96.
- Holsheimer J, Nguyen JP, Lefaucheur JP, Manola L. Cathodal, anodal or bifocal stimulation of the motor cortex in the management of chronic pain? *Acta Neurochir Suppl* 2007b;97:57–66.
- Hubli M, Dietz V, Schraff-Altarmatt M, Bolliger M. Modulation of spinal neuronal excitability by spinal direct currents and locomotion after spinal cord injury. *Clin Neurophysiol* 2013;124:1187–95.
- Hummel F, Celnik P, Giraux P, Floel A, Wu WH, Gerloff C, et al. Effects of non-invasive cortical stimulation on skilled motor function in chronic stroke. *Brain* 2005;128:490–9.
- Hummel FC, Voller B, Celnik P, Floel A, Giraux P, Gerloff C, et al. Effects of brain polarization on reaction times and pinch force in chronic stroke. *BMC Neurosci* 2006;7:73.
- Hyyriäinen P, Mäkitie A, Aarnisalo AA. Self-Administered domiciliary tDCS treatment for tinnitus: a double-blind sham-controlled study. *PLoS One* 2016;11:e0154286.
- Iodice R, Dubbioso R, Ruggiero L, Santoro L, Manganeli F. Anodal transcranial direct current stimulation of motor cortex does not ameliorate spasticity in multiple sclerosis. *Restor Neurol Neurosci* 2015;33:487–92.
- Jales Jr LH, Costa MD, Jales Neto LH, Ribeiro JP, Freitas WJ, Teixeira MJ. Transcranial direct current stimulation in fibromyalgia: effects on pain and quality of life evaluated clinically and by brain perfusion scintigraphy. *Rev Dor São Paulo* 2015;16:37–42.
- Jauch-Chara K, Kistenmacher A, Herzog N, Schwarz M, Schweiger U, Oltmanns KM. Repetitive electric brain stimulation reduces food intake in humans. *Am J Clin Nutr* 2014;100:1003–9.
- Jayaram G, Tang B, Pallegadda R, Vasudevan EV, Celnik P, Bastian A. Modulating locomotor adaptation with cerebellar stimulation. *J Neurophysiol* 2012;107:2950–7.
- Jefferys JG. Nonsynaptic modulation of neuronal activity in the brain: electric currents and extracellular ions. *Physiol Rev* 1995;75:689–723.
- Johansen-Berg H, Dawes H, Guy C, Smith SM, Wade DT, Matthews PM. Correlation between motor improvements and altered fMRI activity after rehabilitative therapy. *Brain* 2002a;125:2731–42.
- Johansen-Berg H, Rushworth MF, Bogdanovic MD, Kischka U, Wimalaratna S, Matthews PM. The role of ipsilateral premotor cortex in hand movement after stroke. *Proc Natl Acad Sci USA* 2002b;99:14518–23.
- Joos K, Vanneste S, De Ridder D. Disentangling depression and distress networks in the tinnitus brain. *PLoS One* 2012;7:e40544.
- Joos K, De Ridder D, Van de Heyning P, Vanneste S. Polarity specific suppression effects of transcranial direct current stimulation for tinnitus. *Neural Plast* 2014;2014:930860.
- Joos K, De Ridder D, Vanneste S. The differential effect of low- versus high-frequency random noise stimulation in the treatment of tinnitus. *Exp Brain Res* 2015;233:1433–40.
- Jung IY, Lim JY, Kang EK, Sohn HM, Paik NJ. The factors associated with good responses to speech therapy combined with transcranial direct current stimulation in post-stroke aphasic patients. *Ann Rehabil Med* 2011;35:460–9.
- Kabakov AV, Muller PA, Pascual-Leone A, Jensen FE, Rotenberg A. Contribution of axonal orientation to pathway-dependent modulation of excitatory transmission by direct current stimulation in isolated rat hippocampus. *J Neurophysiol* 2012;107:1881–9.
- Kalu UG, Sexton CE, Loo CK, Ebmeier KP. Transcranial direct current stimulation in the treatment of major depression: a meta-analysis. *Psychol Med* 2012;42:1791–800.
- Kang EK, Kim YK, Sohn HM, Cohen LG, Paik NJ. Improved picture naming in aphasia patients treated with cathodal tDCS to inhibit the right Broca's homologue area. *Restor Neurol Neurosci* 2011;29:141–52.
- Kang N, Summers JJ, Cauraugh JH. Transcranial direct current stimulation facilitates motor learning post-stroke: a systematic review and meta-analysis. *J Neurol Neurosurg Psychiatry* 2016;87:345–55.
- Kaski D, Allum JH, Bronstein AM, Dominguez RO. Applying anodal tDCS during tango dancing in a patient with Parkinson's disease. *Neurosci Lett* 2014a;568:39–43.

- Kaski D, Dominguez RO, Allum JH, Islam AF, Bronstein AM. Combining physical training with transcranial direct current stimulation to improve gait in Parkinson's disease: a pilot randomized controlled study. *Clin Rehabil* 2014b;28:1115–24.
- Kasschau M, Sherman K, Haider L, Frontario A, Shaw M, Datta A, et al. A protocol for the use of remotely-supervised transcranial direct current stimulation (tDCS) in multiple sclerosis (MS). *J Vis Exp* 2015;106:e53542.
- Keeser D, Meindl T, Bor J, Palm U, Pogarell O, Mulert C, et al. Prefrontal transcranial direct current stimulation changes connectivity of resting-state networks during fMRI. *J Neurosci* 2011a;31:15284–93.
- Keeser D, Padberg F, Reisinger E, Pogarell O, Kirsch V, Palm U, et al. Prefrontal direct current stimulation modulates resting EEG and event-related potentials in healthy subjects: a standardized low resolution tomography (sLORETA) study. *Neuroimage* 2011b;55:644–57.
- Kekic M, McClelland J, Campbell I, Nestler S, Rubia K, David AS, et al. The effects of prefrontal cortex transcranial direct current stimulation (tDCS) on food craving and temporal discounting in women with frequent food cravings. *Appetite* 2014;78:55–62.
- Kessler SK, Turkeltaub PE, Benson JG, Hamilton RH. Differences in the experience of active and sham transcranial direct current stimulation. *Brain Stimul* 2012;5:155–62.
- Khedr EM, Shawky OA, El-Hammady DH, Rothwell JC, Darwish ES, Mostafa OM, et al. Effect of anodal versus cathodal transcranial direct current stimulation on stroke rehabilitation: a pilot randomized controlled trial. *Neurorehabil Neural Repair* 2013;27:592–601.
- Khedr EM, Abo El-Fetoh N, Ali AM, El-Hammady DH, Khalifa H, Atta H, et al. Dual-hemisphere repetitive transcranial magnetic stimulation for rehabilitation of poststroke aphasia: a randomized, double-blind clinical trial. *Neurorehabil Neural Repair* 2014a;28:740–50.
- Khedr EM, Gamal NF, El-Fetoh NA, Khalifa H, Ahmed EM, Ali AM, et al. A double-blind randomized clinical trial on the efficacy of cortical direct current stimulation for the treatment of Alzheimer's disease. *Front Aging Neurosci* 2014b;6:275.
- Klein MM, Treister R, Raji T, Pascual-Leone A, Park L, Nurmikko T, et al. Transcranial magnetic stimulation of the brain: guidelines for pain treatment research. *Pain* 2015;156:1601–14.
- Kim YJ, Ku J, Kim HJ, Im DJ, Lee HS, Han KA, et al. Randomized, sham controlled trial of transcranial direct current stimulation for painful diabetic polyneuropathy. *Ann Rehabil Med* 2013;37:766–76.
- Kiran S. What is the nature of poststroke language recovery and reorganization? *ISRN Neurol* 2012;2012:786872.
- Kirson ED, Dbalý V, Tovarys F, Vymazal J, Soustiel JF, Itzhaki A, et al. Alternating electric fields arrest cell proliferation in animal tumor models and human brain tumors. *Proc Natl Acad Sci USA* 2007;104:10152–7.
- Klauss J, Penido Pinheiro LC, Silva Merlo BL, de Almeida Correia Santos G, Fregni F, Nitsche MA, et al. A randomized controlled trial of targeted prefrontal cortex modulation with tDCS in patients with alcohol dependence. *Int J Neuropsychopharmacol* 2014;17:1793–803.
- Koenigs M, Grafman J. The functional neuroanatomy of depression: distinct roles for ventromedial and dorsolateral prefrontal cortex. *Behav Brain Res* 2009;201:239–43.
- Kumar S, Wagner CW, Frayne C, Zhu L, Selim M, Feng W, et al. Noninvasive brain stimulation may improve stroke-related dysphagia: a pilot study. *Stroke* 2011;42:1035–40.
- Kuo MF, Nitsche MA. Effects of transcranial electrical stimulation on cognition. *Clin EEG Neurosci* 2012;43:192–9.
- Kuo HI, Paulus W, Batsikadze G, Jamil A, Kuo MF, Nitsche MA. Chronic enhancement of serotonin facilitates excitatory transcranial direct current stimulation-induced neuroplasticity. *Neuropsychopharmacology* 2016;41:1223–30.
- Kurimori M, Shiozawa P, Bikson M, Aboseria M, Cordeiro Q. Targeting negative symptoms in schizophrenia: results from a proof-of-concept trial assessing prefrontal anodic tDCS protocol. *Schizophr Res* 2015;166:362–3.
- Lamy JC, Ho C, Badel A, Arrigo RT, Boakye M. Modulation of soleus H reflex by spinal DC stimulation in humans. *J Neurophysiol* 2012;108:906–14.
- Langguth B, Landgrebe M, Kleinjung T, Sand GP, Hajak G. Tinnitus and depression. *World J Biol Psychiatry* 2011;12:489–500.
- Langguth B, Kreuzer PM, Kleinjung T, De Ridder D. Tinnitus: causes and clinical management. *Lancet Neurol* 2013;12:920–30.
- Laska AC, Hellblom A, Murray V, Kahan T, Von Arbin M. Aphasia in acute stroke and relation to outcome. *J Intern Med* 2001;249:413–22.
- Lazar RM, Minzer B, Antonelli D, Festa JR, Krakauer JW, Marshall RS. Improvement in aphasia scores after stroke is well predicted by initial severity. *Stroke* 2010;41:1485–8.
- Lee SY, Cheon HJ, Yoon KJ, Chang WH, Kim YH. Effects of dual transcranial direct current stimulation for aphasia in chronic stroke patients. *Ann Rehabil Med* 2013;37:603–10.
- Lee SJ, Chun MH. Combination transcranial direct current stimulation and virtual reality therapy for upper extremity training in patients with subacute stroke. *Arch Phys Med Rehabil* 2014;95:431–8.
- Lefaucheur JP. The use of repetitive transcranial magnetic stimulation (rTMS) in chronic neuropathic pain. *Neurophysiol Clin* 2006;36:117–24.
- Lefaucheur JP. Methods of therapeutic cortical stimulation. *Neurophysiol Clin* 2009;39:1–14.
- Lefaucheur JP. Neurophysiology of cortical stimulation. *Int Rev Neurobiol* 2012;107:57–85.
- Lefaucheur JP, Drouot X, Menard-Lefaucheur I, Zerah F, Bendib B, Cesaro P, et al. Neurogenic pain relief by repetitive transcranial magnetic cortical stimulation depends on the origin and the site of pain. *J Neurol Neurosurg Psychiatry* 2004;75:612–6.
- Lefaucheur JP, Hatem S, Nineb A, Ménard-Lefaucheur I, Wendling S, Keravel Y, et al. Somatotopic organization of the analgesic effects of motor cortex rTMS in neuropathic pain. *Neurology* 2006;67:1998–2004.
- Lefaucheur JP, Holsheimer J, Goujon C, Keravel Y, Nguyen JP. Descending volleys generated by efficacious epidural motor cortex stimulation in patients with chronic neuropathic pain. *Exp Neurol* 2010;223:609–14.
- Lefaucheur JP, André-Obadia N, Antal A, Ayache SS, Baeken C, Benninger DH, et al. Evidence-based guidelines on the therapeutic use of repetitive transcranial magnetic stimulation (rTMS). *Clin Neurophysiol* 2014;125:2150–206.
- Lefebvre S, Laloux P, Peeters A, Desfontaines P, Jamart J, Vandermeeren Y. Dual-tDCS enhances online motor skill learning and long-term retention in chronic stroke patients. *Front Hum Neurosci* 2012;6:343.
- Lefebvre S, Thonnard JL, Laloux P, Peeters A, Jamart J, Vandermeeren Y. Single session of dual-tDCS transiently improves precision grip and dexterity of the paretic hand after stroke. *Neurorehabil Neural Repair* 2014;28:100–10.
- Levasseur-Moreau J, Brunelin J, Fecteau S. Non-invasive brain stimulation can induce paradoxical facilitation. Are these neuroenhancements transferable and meaningful to security services? *Front Hum Neurosci* 2013;7:449.
- Liebetanz D, Nitsche MA, Tergau F, Paulus W. Pharmacological approach to the mechanisms of transcranial DC-stimulation-induced after-effects of human motor cortex excitability. *Brain* 2002;125:2238–47.
- Lim CY, Shin HI. Noninvasive DC stimulation on neck changes MEP. *Neuroreport* 2011;22:819–23.
- Lindenbergh R, Renga V, Zhu LL, Nair D, Schlaug G. Bihemispheric brain stimulation facilitates motor recovery in chronic stroke patients. *Neurology* 2010;75:2176–84.
- Lindenbergh R, Sieg MM, Meinzer M, Nachtigall L, Flöel A. Neural correlates of unihemispheric and bihemispheric motor cortex stimulation in healthy young adults. *Neuroimage* 2016;140:141–9.
- Liu A, Bryant A, Jefferson A, Friedman D, Minhas P, Barnard S, et al. Exploring the efficacy of a 5-day course of transcranial direct current stimulation (tDCS) on depression and memory function in patients with well-controlled temporal lobe epilepsy. *Epilepsy Behav* 2016;55:11–20.
- Ljubisavljevic M, Maxood K, Bjekic J, Oommen J, Nagelkerke N. Long-term effects of repeated prefrontal cortex transcranial direct current stimulation (tDCS) on food craving in normal and overweight young adults. *Brain Stimul* 2016. <http://dx.doi.org/10.1016/j.brs.2016.07.002>. in press.
- Lolas F. Brain polarization: behavioral and therapeutic effects. *Biol Psychiatry* 1977;12:37–47.
- Loo CK, Sachdev P, Martin DM, Pigot M, Alonzo A, Malhi GS, et al. A double-Blind, sham-controlled trial of transcranial direct current stimulation for the treatment of depression. *Int J Neuropsychopharmacol* 2010;13:61–9.
- Loo CK, Martin DM, Alonzo A, Gandevia S, Mitchell PB, Sachdev P. Avoiding skin burns with transcranial direct current stimulation: preliminary considerations. *Int J Neuropsychopharmacol* 2011;14:425–6.
- Loo CK, Alonzo A, Martin DM, Mitchel PB, Galvez V, Sachdev P. Transcranial direct current stimulation for depression: 3-week, randomized, sham-controlled trial. *Br J Psychiatry* 2012;200:52–9.
- Lopez-Alonso V, Cheeran B, Rio-Rodriguez D, Fernandez-Del-Olmo M. Inter-individual variability in response to non-invasive brain stimulation paradigms. *Brain Stimul* 2014;7:372–80.
- Lopez-Alonso V, Fernandez-Del-Olmo M, Costantini A, Gonzalez-Henriquez JJ, Cheeran B. Intra-individual variability in the response to anodal transcranial direct current stimulation. *Clin Neurophysiol* 2015;126:2342–7.
- Luedtke K, May A, Jurgens TP. No effect of a single session of transcranial direct current stimulation on experimentally induced pain in patients with chronic low back pain – an exploratory study. *PLoS One* 2012;7:e48857.
- Luedtke K, Rushton A, Wright C, Jürgens T, Polzer A, Mueller G, et al. Effectiveness of transcranial direct current stimulation preceding cognitive behavioural management for chronic low back pain: sham controlled double blinded randomised controlled trial. *BMJ* 2015;350:h1640.
- Macher K, Bohringer A, Villringer A, Pleger B. Cerebellar-parietal connections underpin phonological storage. *J Neurosci* 2014;34:5029–37.
- Mahmoudi H, Borhani Haghghi A, Petramfar P, Jahanshahi S, Salehi Z, Fregni F. Transcranial direct current stimulation: electrode montage in stroke. *Disabil Rehabil* 2011;33:1383–8.
- Mailis-Gagnon A, Furlan AD, Sandoval JA. Taylor R Spinal cord stimulation for chronic pain. *Cochrane Database Syst Rev* 2004;3:CD003783.
- Manenti R, Brambilla M, Rosini S, Orizio I, Ferrari C, Borroni B, et al. Time up and go task performance improves after transcranial direct current stimulation in patient affected by Parkinson's disease. *Neurosci Lett* 2014;580:74–7.
- Manenti R, Petesi M, Brambilla M, Rosini S, Miozzo A, Padovani A, et al. Efficacy of semantic-phonological treatment combined with tDCS for verb retrieval in a patient with aphasia. *Neurocase* 2015;21:109–19.
- Manenti R, Brambilla M, Benussi A, Rosini S, Cobelli C, Ferrari C, et al. Mild cognitive impairment in Parkinson's disease is improved by transcranial direct current stimulation combined with physical therapy. *Mov Disord* 2016;31:715–24.
- Manola L, Roelofsens BH, Holsheimer J, Marani E, Geelen J. Modelling motor cortex stimulation for chronic pain control: electrical potential field, activating functions and responses of simple nerve fibre models. *Med Biol Eng Comput* 2005;43:335–43.

- Marangolo P, Marinelli CV, Bonifazi S, Fiori V, Ceravolo MG, Provinciali L, et al. Electrical stimulation over the left inferior frontal gyrus (IFG) determines long-term effects in the recovery of speech apraxia in three chronic aphasics. *Behav Brain Res* 2011;225:498–504.
- Marangolo P, Fiori V, Calpagnano MA, Campana S, Razzano C, Caltagirone C, et al. tDCS over the left inferior frontal cortex improves speech production in aphasia. *Front Hum Neurosci* 2013a;7:539.
- Marangolo P, Fiori V, Cipollari S, Campana S, Razzano C, Di Paola M, et al. Bihemispheric stimulation over left and right inferior frontal region enhances recovery from apraxia of speech in chronic aphasia. *Eur J Neurosci* 2013b;38:3370–7.
- Marangolo P, Fiori V, Di Paola M, Cipollari S, Razzano C, Oliveri M, et al. Differential involvement of the left frontal and temporal regions in verb naming: a tDCS treatment study. *Restor Neurol Neurosci* 2013c;31:63–72.
- Marangolo P, Fiori V, Campana S, Calpagnano MA, Razzano C, Caltagirone C, et al. Something to talk about: enhancement of linguistic cohesion through tDCS in chronic non fluent aphasia. *Neuropsychologia* 2014a;53:246–56.
- Marangolo P, Fiori V, Gelfo F, Shofany J, Razzano C, Caltagirone C, et al. Bihemispheric tDCS enhances language recovery but does not alter BDNF levels in chronic aphasic patients. *Restor Neurol Neurosci* 2014b;32:367–79.
- Marangolo P, Fiori V, Sabatini U, De Pasquale G, Razzano C, Caltagirone C, et al. Bilateral transcranial direct current stimulation language treatment enhances functional connectivity in the left hemisphere: preliminary data from aphasia. *J Cogn Neurosci* 2016;28:724–38.
- Marshall RS, Perera GM, Lazar RM, Krakauer JW, Constantine RC, DeLaPaz RL. Evolution of cortical activation during recovery from corticospinal tract infarction. *Stroke* 2000;31:656–61.
- Marshall L, Molle M, Hallschmid M, Born J. Transcranial direct current stimulation during sleep improves declarative memory. *J Neurosci* 2004;24:9985–92.
- Marshall L, Helgadóttir H, Mölle M, Born J. Boosting slow oscillations during sleep potentiates memory. *Nature* 2006;444:610–3.
- Martin DM, Alonzo A, Mitchell PB, Sachdev P, Galvez V, Loo CK. Fronto-extracerebral transcranial direct current stimulation as a treatment for major depression: an open-label pilot study. *J Affect Disord* 2011;134:459–63.
- Martin DM, Alonzo A, Ho KA, Player M, Mitchell PB, Sachdev P, et al. Continuation transcranial direct current stimulation for the prevention of relapse in major depression. *J Affect Disord* 2013;25:274–8.
- Maslen H, Douglas T, Cohen Kadosh R, Levy N, Savulescu J. Do-it-yourself brain stimulation: a regulatory model. *J Med Ethics* 2015;41:413–4.
- Massaquoi SG. Physiology of clinical dysfunction of the cerebellum. *Handb Clin Neurol* 2012;103:37–62.
- Matsunaga K, Nitsche MA, Tsuji S, Rothwell JC. Effect of transcranial DC sensorimotor cortex stimulation on somatosensory evoked potentials in humans. *Clin Neurophysiol* 2004;115:456–60.
- Mattai A, Miller R, Weisinger B, Greenstein D, Bakalar J, Tossell J, et al. Tolerability of transcranial direct current stimulation in childhood-onset schizophrenia. *Brain Stimul* 2011;4:275–80.
- Mattioli F, Bellomi F, Stampatori C, Capra R, Miniussi C. Neuroenhancement through cognitive training and anodal tDCS in multiple sclerosis. *Mult Scler* 2016;22:222–30.
- McFadden JL, Borckardt JJ, George MS, Beam W. Reducing procedural pain and discomfort associated with transcranial direct current stimulation. *Brain Stimul* 2011;4:38–42.
- Meesen RL, Thijs H, Leenus DJ, Cuyppers K. A single session of 1 mA anodal tDCS-supported motor training does not improve motor performance in patients with multiple sclerosis. *Restor Neurol Neurosci* 2014;32:293–300.
- Mehta AR, Brittain JS, Brown P. The selective influence of rhythmic cortical versus cerebellar transcranial stimulation on human physiological tremor. *J Neurosci* 2014;34:7501–8.
- Meinzer M, Darrow R, Lindenberg R, Flöel A. Electrical stimulation of the motor cortex enhances treatment outcome in post-stroke aphasia. *Brain* 2016;139:1152–63.
- Mellerio C, Farhat WH, Calvet D, Oppenheim C, Lefaucheur JP, Bartolucci P. Cerebral reorganization of language and motor control secondary to chronic hemispheric vasculopathy in a patient with homozygous sickle-cell disease. *Am J Hematol* 2014;89:662–3.
- Mendonca ME, Santana MB, Baptista AF, Datta A, Bikson M, Fregni F, et al. Transcranial DC stimulation in fibromyalgia: optimized cortical target supported by high-resolution computational models. *J Pain* 2011;12:610–7.
- Meron D, Hedger N, Garner M, Baldwin DS. Transcranial direct current stimulation (tDCS) in the treatment of depression: systematic review and meta-analysis of efficacy and tolerability. *Neurosci Biobehav Rev* 2015;57:46–62.
- Minichino A, Bersani FS, Spagnoli F, Corrado A, De Michele F, Calò WK, et al. Prefronto-cerebellar transcranial direct current stimulation improves sleep quality in euthymic bipolar patients: a brief report. *Behav Neurol* 2014;2014:876521.
- Minichino A, Bersani FS, Bernabei L, Spagnoli F, Vergnani L, Corrado A, et al. Prefronto-cerebellar transcranial direct current stimulation improves visuospatial memory, executive functions, and neurological soft signs in patients with euthymic bipolar disorder. *Neuropsychiatr Dis Treat* 2015;11:2265–70.
- Miranda PC, Faria P, Hallett M. What does the ratio of injected current to electrode area tell us about current density in the brain during tDCS? *Clin Neurophysiol* 2009;120:1183–7.
- Moliadze V, Antal A, Paulus W. Boosting brain excitability by transcranial high frequency stimulation in the ripple range. *J Physiol (London)* 2010;588:4891–904.
- Moliadze V, Antal A, Paulus W. Close to threshold transcranial electrical stimulation preferentially activates inhibitory networks before switching to excitation with higher intensities. *Brain Stimul* 2012;5:505–11.
- Moliadze V, Fritzsche G, Antal A. Comparing the efficacy of excitatory transcranial stimulation methods measuring motor evoked potentials. *Neural Plast* 2014;2014:837141.
- Mondino M, Bannabi D, Poulet E, Galvao F, Brunelin J, Haffen E. Can transcranial direct current stimulation (tDCS) alleviate symptoms and improve cognition in psychiatric disorders? *World J Biol Psychiatry* 2014;15:261–75.
- Mondino M, Haesebaert F, Poulet E, Suaud-Chagny MF, Brunelin J. Fronto-temporal transcranial direct current stimulation (tDCS) reduces source-monitoring deficits and auditory hallucinations in patients with schizophrenia. *Schizophr Res* 2015;161:515–6.
- Mondino M, Jardri R, Suaud-Chagny MF, Saoud M, Poulet E, Brunelin J. Effects of fronto-temporal transcranial direct current stimulation on auditory verbal hallucinations and resting-state functional connectivity of the left temporoparietal junction in patients with schizophrenia. *Schizophr Bull* 2016;42:318–26.
- Monte-Silva K, Kuo MF, Liebetanz D, Paulus W, Nitsche MA. Shaping the optimal repetition interval for cathodal transcranial direct current stimulation (tDCS). *J Neurophysiol* 2010a;103:1735–40.
- Monte-Silva K, Liebetanz D, Grundey J, Paulus W, Nitsche MA. Dosage-dependent non-linear effect of L-dopa on human motor cortex plasticity. *J Physiol (London)* 2010b;588:3415–24.
- Monte-Silva K, Kuo MF, Hesseenthaler S, Fresnoza S, Liebetanz D, Paulus W, et al. Induction of late LTP-like plasticity in the human motor cortex by repeated non-invasive brain stimulation. *Brain Stimul* 2013;6:424–32.
- Monti A, Cogiமானian F, Marceglia S, Ferrucci R, Mamelì F, Mrakic-Spota S, et al. Improved naming after transcranial direct current stimulation in aphasia. *J Neurol Neurosurg Psychiatry* 2008;79:451–3.
- Monti A, Ferrucci R, Fumagalli M, Mamelì F, Cogiமானian F, Ardolino G, Priori A. Transcranial direct current stimulation (tDCS) and language. *J Neurol Neurosurg Psychiatry* 2013;84:832–42.
- Mori F, Codecà C, Kusayanagi H, Monteleone F, Buttarì F, Fiore S, et al. Effects of anodal transcranial direct current stimulation on chronic neuropathic pain in patients with multiple sclerosis. *J Pain* 2010;11:436–42.
- Mori F, Nicoletti CG, Kusayanagi H, Foti C, Restivo DA, Marciani MG, et al. Transcranial direct current stimulation ameliorates tactile sensory deficit in multiple sclerosis. *Brain Stimul* 2013;6:654–9.
- Mortensen J, Figlewski K, Andersen H. Combined transcranial direct current stimulation and home-based occupational therapy for upper limb motor impairment following intracerebral hemorrhage: a double-blind randomized controlled trial. *Disabil Rehabil* 2016;38:637–43.
- Mrakic-Spota S, Marceglia S, Mamelì F, Dilena R, Tadini L, Priori A. Transcranial direct current stimulation in two patients with Tourette syndrome. *Mov Disord* 2008;23:2259–61.
- Müller-Dahlhaus F, Ziemann U. Metaplasticity in human cortex. *Neuroscientist* 2015;21:185–202.
- Murase N, Duque J, Mazzocchio R, Cohen LG. Influence of interhemispheric interactions on motor function in chronic stroke. *Ann Neurol* 2004;55:400–9.
- Mylius V, Borckardt JJ, Lefaucheur JP. Noninvasive cortical modulation of experimental pain. *Pain* 2012;153:1350–63.
- Nair DG, Renga V, Lindenberg R, Zhu L, Schlaug G. Optimizing recovery potential through simultaneous occupational therapy and non-invasive brain-stimulation using tDCS. *Restor Neurol Neurosci* 2011;29:411–20.
- Nakamura-Palacios EM, de Almeida Benevides MC, da Penha Zago-Gomes M, de Oliveira RW, de Vasconcelos VF, de Castro LN, et al. Auditory event-related potentials (P3) and cognitive changes induced by frontal direct current stimulation in alcoholics according to Lesch alcoholism typology. *Int J Neuropsychopharmacol* 2012;15:601–16.
- Nakamura-Palacios EM, Lopes IB, Souza RA, Klaus J, Batista EK, Conti CL, et al. Ventral medial prefrontal cortex (vmPFC) as a target of the dorsolateral prefrontal modulation by transcranial direct current stimulation (tDCS) in drug addiction. *J Neural Transm (Vienna)* 2016;123:1179–94.
- Naro A, Calabrò RS, Russo M, Leo A, Pollicino P, Quartarone A, et al. Can transcranial direct current stimulation be useful in differentiating unresponsive wakefulness syndrome from minimally conscious state patients? *Restor Neurol Neurosci* 2015;33:159–76.
- Naro A, Russo M, Leo A, Cannavò A, Manuli A, Bramanti A, et al. Cortical connectivity modulation induced by cerebellar oscillatory transcranial direct current stimulation in patients with chronic disorders of consciousness: a marker of covert cognition? *Clin Neurophysiol* 2016;127:1845–54.
- Nguyen JP, Nizard J, Keravel Y, Lefaucheur JP. Invasive brain stimulation for the treatment of neuropathic pain. *Nat Rev Neurol* 2011;7:699–709.
- Nienow TM, MacDonald 3rd AW, Lim KO. tDCS produces incremental gain when combined with working memory training in patients with schizophrenia: a proof of concept pilot study. *Schizophr Res* 2016;172:218–9.
- Niérat MC, Similowski T, Lamy JC. Does trans-spinal direct current stimulation alter phrenic motoneurons and respiratory neuromechanical outputs in humans? A double-blind, sham-controlled, randomized, crossover study. *J Neurosci* 2014;34:14420–9.
- Nitsche MA, Paulus W. Excitability changes induced in the human motor cortex by weak transcranial direct current stimulation. *J Physiol (London)* 2000;527:633–9.
- Nitsche MA, Paulus W. Sustained excitability elevations induced by transcranial DC motor cortex stimulation in humans. *Neurology* 2001;57:1899–901.

- Nitsche MA, Fricke K, Henschke U, Schlitterlau A, Liebetanz D, Lang N, et al. Pharmacological modulation of cortical excitability shifts induced by transcranial direct current stimulation in humans. *J Physiol (London)* 2003a;553:293–301.
- Nitsche MA, Liebetanz D, Antal A, Lang N, Tergau F, Paulus W. Modulation of cortical excitability by weak direct current stimulation—technical, safety and functional aspects. *Suppl Clin Neurophysiol* 2003b;56:255–76.
- Nitsche MA, Schauenburg A, Lang N, Liebetanz D, Exner C, Paulus W, et al. Facilitation of implicit motor learning by weak transcranial direct current stimulation of the primary motor cortex in the human. *J Cogn Neurosci* 2003c;15:619–26.
- Nitsche MA, Lampe C, Antal A, Liebetanz D, Lang N, Tergau F, et al. Dopaminergic modulation of long-lasting direct current-induced cortical excitability changes in the human motor cortex. *Eur J Neurosci* 2006;23:1651–7.
- Nitsche MA, Kuo MF, Grosch J, Bergner C, Monte-Silva K, Paulus W. D1-receptor impact on neuroplasticity in humans. *J Neurosci* 2009a;29:2648–53.
- Nitsche MA, Kuo MF, Karrasch R, Wächter B, Liebetanz D, Paulus W. Serotonin affects transcranial direct current-induced neuroplasticity in humans. *Biol Psychiatry* 2009b;66:503–8.
- Nitsche MA, Müller-Dahlhaus F, Paulus W, Ziemann U. The pharmacology of neuroplasticity induced by non-invasive brain stimulation: building models for the clinical use of CNS active drugs. *J Physiol (London)* 2012;590:4641–62.
- O'Connell NE, Cossar J, Marston L, Wand BM, Bunce D, De Souza LH, et al. Transcranial direct current stimulation of the motor cortex in the treatment of chronic nonspecific low back pain: a randomized, double-blind exploratory study. *Clin J Pain* 2013;29:26–34.
- O'Neill F, Sacco P, Nurmikko T. Evaluation of a home-based transcranial direct current stimulation (tDCS) treatment device for chronic pain: study protocol for a randomised controlled trial. *Trials* 2015;16:186.
- O'Shea J, Boudrias MH, Stagg CJ, Bachtar V, Kischka U, Blicher JU, et al. Predicting behavioural response to tDCS in chronic motor stroke. *Neuroimage* 2014;85:924–33.
- Ochi M, Saeki S, Oda T, Matsushima Y, Hachisuka K. Effects of anodal and cathodal transcranial direct current stimulation combined with robotic therapy on severely affected arms in chronic stroke patients. *J Rehabil Med* 2013;45:137–40.
- Oliveira JF, Zanao TA, Valiengo L, Lotufo PA, Bensenor IM, Fregni F, et al. Acute working memory improvement after tDCS in antidepressant-free patients with major depressive disorder. *Neurosci Lett* 2013;537:60–4.
- Oliveira LB, Lopes TS, Soares C, Maluf R, Goes BT, Sá KN, et al. Transcranial direct current stimulation and exercises for treatment of chronic temporomandibular disorders: a blind randomised-controlled trial. *J Oral Rehabil* 2015;42:723–32.
- Pal N, Maire R, Stephan MA, Herrmann FR, Benninger DH. Transcranial direct current stimulation for the treatment of chronic tinnitus: a randomized controlled study. *Brain Stimul* 2015;8:1101–7.
- Palm U, Keeser D, Schiller C, Fintescu Z, Reisinger E, Baghai TC, et al. Transcranial direct current stimulation in a patient with therapy-resistant major depression. *World J Biol Psychiatry* 2009;10:632–5.
- Palm U, Schiller C, Fintescu Z, Obermeier M, Keeser D, Reisinger E, et al. Transcranial direct current stimulation in treatment resistant depression: a randomized double-blind, placebo-controlled study. *Brain Stimul* 2012;5:242–51.
- Palm U, Hasan A, Keeser D, Falkai P, Padberg F. Transcranial random noise stimulation for the treatment of negative symptoms in schizophrenia. *Schizophr Res* 2013a;146:372–3.
- Palm U, Keeser D, Blautzik J, Pogarell O, Ertl-Wagner B, Kupka MJ, et al. Prefrontal transcranial direct current stimulation (tDCS) changes negative symptoms and functional connectivity MRI (fcMRI) in a single case of treatment-resistant schizophrenia. *Schizophr Res* 2013b;150:583–5.
- Palm U, Ayache SS, Padberg F, Lefaucheur JP. Non-invasive brain stimulation therapy in multiple sclerosis: a review of tDCS, rTMS and ECT results. *Brain Stimul* 2014a;7:849–54.
- Palm U, Feichtner KB, Hasan A, Gauglitz G, Langguth B, Nitsche MA, Keeser D, Padberg F. The role of contact media at the skin-electrode interface during transcranial direct current stimulation (tDCS). *Brain Stimul* 2014b;7:762–4.
- Palm U, Chalah MA, Padberg F, Al-Ani T, Abdelloumi M, Sorel M, et al. Effects of transcranial random noise stimulation (tRNS) on affect, pain, and attention in multiple sclerosis. *Restor Neurol Neurosci* 2016a;34:189–99.
- Palm U, Keeser D, Hasan A, Kupka MJ, Blautzik J, Sarubin N, et al. Prefrontal transcranial direct current stimulation for treatment of schizophrenia with predominant negative symptoms: a double-blind, Sham-controlled proof-of-concept study. *Schizophr Bull* 2016b;42:1253–61.
- Parazzini M, Focchi S, Ravazzani P. Electric field and current density distribution in an anatomical head model during transcranial direct current stimulation for tinnitus treatment. *Bioelectromagnetics* 2012;33:476–87.
- Parazzini M, Focchi S, Liorni I, Rossi E, Cogliamariani F, Vergari M, et al. Modeling the current density generated by transcutaneous spinal direct current stimulation (tsDCS). *Clin Neurophysiol* 2014a;125:2260–70.
- Parazzini M, Rossi E, Ferrucci R, Liorni I, Priori A, Ravazzani P. Modelling the electric field and the current density generated by cerebellar transcranial DC stimulation in humans. *Clin Neurophysiol* 2014b;125:577–84.
- Paulus W. Transcranial electrical stimulation (tES - tDCS; tRNS, tACS) methods. *Neuropsychol Rehabil* 2011;21:602–17.
- Paulus W, Rothwell JC. Membrane resistance and shunting inhibition: where biophysics meets state-dependent human neurophysiology. *J Physiol (London)* 2016;594:2719–28.
- Pelletier SJ, Lagacé M, St-Amour I, Arsenault D, Cisbani G, Chabrat A. The morphological and molecular changes of brain cells exposed to direct current electric field stimulation. *Neuropsychopharmacol* 2014;18. pii: pyu090.
- Peña-Gómez C, Sala-Lonch R, Junqué C, Clemente IC, Vidal D, Bargalló N, et al. Modulation of large-scale brain networks by transcranial direct current stimulation evidenced by resting-state functional MRI. *Brain Stimul* 2012;5:252–63.
- Pereira JB, Junqué C, Bartrés-Faz D, Martí MJ, Sala-Llonch R, Compta Y, et al. Modulation of verbal fluency networks by transcranial direct current stimulation (tDCS) in Parkinson's disease. *Brain Stimul* 2013;6:16–24.
- Pérez-Borrego YA, Campolo M, Soto-León V, Rodríguez-Matas MJ, Ortega E, Oliviero A. Pain treatment using tDCS in a single patient: tele-medicine approach in non-invasive brain stimulation. *Brain Stimul* 2014;7:334–5.
- Perrotta A, Bolla M, Anastasio MG, Serrao M, Sandrini G, Pierelli F. Modulation of temporal summation threshold of the nociceptive withdrawal reflex by transcutaneous spinal direct current stimulation in humans. *Clin Neurophysiol* 2016;127:755–61.
- Picelli A, Chemello E, Castellazzi P, Roncari L, Waldner A, Saltuari L, et al. Combined effects of transcranial direct current stimulation (tDCS) and transcutaneous spinal direct current stimulation (tsDCS) on robot-assisted gait training in patients with chronic stroke: a pilot, double blind, randomized controlled trial. *Restor Neurol Neurosci* 2015;33:357–68.
- Pisegna JM, Kaneoka A, Pearson Jr WG, Kumar S, Langmore SE. Effects of non-invasive brain stimulation on post-stroke dysphagia: a systematic review and meta-analysis of randomized controlled trials. *Clin Neurophysiol* 2016;127:956–68.
- Plewnia C, Zwissler B, Längst I, Maurer B, Giel K, Krüger R. Effects of transcranial direct current stimulation (tDCS) on executive functions: influence of COMT Val/Met polymorphism. *Cortex* 2013;49:1801–7.
- Polanía R, Nitsche MA, Paulus W. Modulating functional connectivity patterns and topological functional organization of the human brain with transcranial direct current stimulation. *Hum Brain Mapp* 2011a;32:1236–49.
- Polanía R, Paulus W, Antal A, Nitsche MA. Introducing graph theory to track for neuroplastic alterations in the resting human brain: a transcranial direct current stimulation study. *Neuroimage* 2011b;54:2287–96.
- Polanía R, Paulus W, Nitsche MA. Modulating cortico-striatal and thalamo-cortical functional connectivity with transcranial direct current stimulation. *Hum Brain Mapp* 2012;33:2499–508.
- Polanowska KE, Leśniak MM, Seniów JB, Czepiel W, Członkowska A. Anodal transcranial direct current stimulation in early rehabilitation of patients with post-stroke non-fluent aphasia: a randomized, double-blind, sham-controlled pilot study. *Restor Neurol Neurosci* 2013a;31:761–71.
- Polanowska KE, Leśniak M, Seniów JB, Członkowska A. No effects of anodal transcranial direct current stimulation on language abilities in early rehabilitation of post-stroke aphasic patients. *Neurol Neurochir Pol* 2013b;47:414–22.
- Pope PA, Miall RC. Task-specific facilitation of cognition by cathodal transcranial direct current stimulation of the cerebellum. *Brain Stimul* 2012;5:84–94.
- Poreisz C, Boros K, Antal A, Paulus W. Safety aspects of transcranial direct current stimulation concerning healthy subjects and patients. *Brain Res Bull* 2007;72:208–14.
- Priori A. Brain polarization in humans: a reappraisal of an old tool for prolonged non-invasive modulation of brain excitability. *Clin Neurophysiol* 2003;114:589–95.
- Priori A, Berardelli A, Rona S, Accornero N, Manfredi M. Polarization of the human motor cortex through the scalp. *Neuroreport* 1998;9:2257–60.
- Priori A, Ciocca M, Parazzini M, Vergari M, Ferrucci R. Transcranial cerebellar direct current stimulation and transcutaneous spinal cord direct current stimulation as innovative tools for neuroscientists. *J Physiol (London)* 2014;592:3345–69.
- Prippl J, Lamm C. Focused transcranial direct current stimulation (tDCS) over the dorsolateral prefrontal cortex modulates specific domains of self-regulation. *Neurosci Res* 2015;91:41–7.
- Prippl J, Neumann R, Kohler U, Lamm C. Effects of transcranial direct current stimulation on risky decision making are mediated by "hot" and "cold" decisions, personality and hemisphere. *Eur J Neurosci* 2013;38:3778–85.
- Purpura DP, McMurtry JG. Intracellular activities and evoked potential changes during polarization of motor cortex. *J Neurophysiol* 1965;28:166–85.
- Quartarone A, Hallett M. Emerging concepts in the physiological basis of dystonia. *Mov Disord* 2013;28:958–67.
- Rahman A, Reato D, Arlotti M, Gasca F, Datta A, Parra LC, et al. Cellular effects of acute direct current stimulation: somatic and synaptic terminal effects. *J Physiol (London)* 2013;591:2563–78.
- Reato D, Rahman A, Bikson M, Parra LC. Effects of weak transcranial alternating current stimulation on brain activity – a review of known mechanisms from animal studies. *Front Hum Neurosci* 2013;7:687.
- Reid SA, Duke LM, Allen JJ. Resting frontal electroencephalographic asymmetry in depression: inconsistencies suggest the need to identify mediating factors. *Psychophysiol* 1998;35:389–404.
- Reis J, Schambra HM, Cohen LG, Buch ER, Fritsch B, Zarahn E, et al. Noninvasive cortical stimulation enhances motor skill acquisition over multiple days through an effect on consolidation. *Proc Natl Acad Sci USA* 2009;106:1590–5.
- Riberto M, Marcon Alfieri F, de Benedetto Monteiro, Pacheco K, Dini Leite V, Nemoto Kaihumi H, Fregni F, et al. Efficacy of transcranial direct current stimulation coupled with a multidisciplinary rehabilitation program for the treatment of fibromyalgia. *Open Rheumatol J* 2011;5:45–50.

- Riggall K, Forlini C, Carter A, Hall W, Weier M, Partridge B, et al. Researchers' perspectives on scientific and ethical issues with transcranial direct current stimulation: an international survey. *Sci Rep* 2015;5:10618.
- Rigonatti SP, Boggio PS, Myczkowski ML, Otta E, Fiquer JT, Ribeiro RB, et al. Transcranial direct current stimulation and fluoxetine for the treatment of depression. *Eur Psychiatry* 2008;23:74–6.
- Riley JD, Le V, Der-Yeghiaian L, See J, Newton JM, Ward NS, et al. Anatomy of stroke injury predicts gains from therapy. *Stroke* 2011;42:421–6.
- Rocha S, Silva E, Foerster Á, Wiesiolek C, Chagas AP, Machado G, et al. The impact of transcranial direct current stimulation (tDCS) combined with modified constraint-induced movement therapy (mCIMT) on upper limb function in chronic stroke: a double-blind randomized controlled trial. *Disabil Rehabil* 2016;38:653–60.
- Roizenblatt S, Fregni F, Gimenez R, Wetzel T, Rigonatti SP, Tufik S, et al. Site-specific effects of transcranial direct current stimulation on sleep and pain in fibromyalgia: a randomized, sham-controlled study. *Pain Pract* 2007;7:297–306.
- Rosset-Llobet J, Fàbregas-Molas S, Pascual-Leone Á. Effect of transcranial direct current stimulation on neurorehabilitation of task-specific dystonia: a double-blind, randomized clinical trial. *Med Probl Perform Art* 2015;30:178–84.
- Rossi C, Sallustio F, Di Legge S, Stanzione P, Koch G. Transcranial direct current stimulation of the affected hemisphere does not accelerate recovery of acute stroke patients. *Eur J Neurol* 2013;20:202–4.
- Ruohonen J, Karhu J. TDCS possibly stimulates glial cells. *Clin Neurophysiol* 2012;123:2006–9.
- Rush S, Driscoll DA. Current distribution in the brain from surface electrodes. *Anaesth Analg Curr Res* 1968;47:717–23.
- Sadleir RJ, Vannorsdall TD, Schretlen DJ, Gordon B. Target optimization in transcranial direct current stimulation. *Front Psychiatry* 2012;3:90.
- Sadnicka A, Hamada M, Bhatia KP, Rothwell JC, Edwards MJ. Cerebellar stimulation fails to modulate motor cortex plasticity in writing dystonia. *Mov Disord* 2014;29:1304–7.
- Saiote C, Goldschmidt T, Timäus C, Steenwijk MD, Opitz A, Antal A, et al. Impact of transcranial direct current stimulation on fatigue in multiple sclerosis. *Restor Neurol Neurosci* 2014;32:423–36.
- Sakrajai P, Janyacharoen T, Jensen MP, Sawanyawisuth K, Auvichayapat N, Tunkamnerdthai O, et al. Pain reduction in myofascial pain syndrome by anodal transcranial direct current stimulation combined with standard treatment: a randomized controlled study. *Clin J Pain* 2014;30:1076–83.
- San-Juan D, Calcáneo Jde D, González-Aragón MF, Bermúdez Maldonado L, Avellán AM, Argumosa EV, et al. Transcranial direct current stimulation in adolescent and adult Rasmussen's encephalitis. *Epilepsy Behav* 2011;20:126–31.
- San-Juan D, Espinoza López DA, Vázquez Gregorio R, Trenado C, González-Aragón MF, Morales-Quezada L, et al. Transcranial direct current stimulation in mesial temporal lobe epilepsy and hippocampal sclerosis. *Brain Stimul* 2016. <http://dx.doi.org/10.1016/j.brs.2016.08.013>. in press.
- Santaracchi E, Feurra M, Galli G, Rossi A, Rossi S. Overclock your brain for gaming? Ethical, social and health care risks. *Brain Stimul* 2013;6:713–4.
- Santaracchi E, Feurra M, Barneschi F, Acampa M, Bianco G, Cioncoloni D, et al. Time course of corticospinal excitability and autonomic function interplay during and following monopolar tDCS. *Front Psychiatry* 2014;5:86.
- Sattler V, Acket B, Raposo N, Albucher JF, Thalamas C, Loubinoux I, et al. Anodal tDCS combined with radial nerve stimulation promotes hand motor recovery in the acute phase after ischemic stroke. *Neurorehabil Neural Repair* 2015;29:743–54.
- Saturnino GB, Antunes A, Thielscher A. On the importance of electrode parameters for shaping electric field patterns generated by tDCS. *Neuroimage* 2015;120:25–35.
- Saunders N, Downham R, Turman B, Kropotov J, Clark R, Yumash R, et al. Working memory training with tDCS improves behavioral and neurophysiological symptoms in pilot group with post-traumatic stress disorder (PTSD) and with poor working memory. *Neurocase* 2015;21:271–8.
- Schmidt SL, Iyengar AK, Foulser AA, Boyle MR, Fröhlich F. Endogenous cortical oscillations constrain neuromodulation by weak electric fields. *Brain Stimul* 2014;7:878–89.
- Segrave RA, Arnold S, Hoy K, Fitzgerald PB. Concurrent cognitive control training augments the antidepressant efficacy of tDCS: a pilot study. *Brain Stimul* 2014;7:325–31.
- Sellers KK, Mellin JM, Lustenberger CM, Boyle MR, Lee WH, Peterchev AV, et al. Transcranial direct current stimulation (tDCS) of frontal cortex decreases performance on the WAIS-IV intelligence test. *Behav Brain Res* 2015;290:32–44.
- Senço NM, Huang Y, D'Urso G, Parra LC, Bikson M, Mantovani A, et al. Transcranial direct current stimulation in obsessive-compulsive disorder: emerging clinical evidence and considerations for optimal montage of electrodes. *Expert Rev Med Devices* 2015;12:381–91.
- Shekhawat GS, Searchfield GD, Stinear CM. Randomized trial of transcranial direct current stimulation and hearing aids for tinnitus management. *Neurorehabil Neural Repair* 2013a;28:410–9.
- Shekhawat GS, Stinear CM, Searchfield GD. Transcranial direct current stimulation intensity and duration effects on tinnitus suppression. *Neurorehabil Neural Repair* 2013b;27:164–72.
- Shekhawat GS, Sundram F, Bikson M, Truong D, De Ridder D, Stinear CM, et al. Intensity, duration, and location of high-definition transcranial direct current stimulation for tinnitus relief. *Neurorehabil Neural Repair* 2016;30:349–59.
- Shigematsu T, Fujishima I, Ohno K. Transcranial direct current stimulation improves swallowing function in stroke patients. *Neurorehabil Neural Repair* 2013;27:363–9.
- Shin YI, Foerster Á, Nitsche MA. Transcranial direct current stimulation (tDCS) – application in neuropsychology. *Neuropsychologia* 2015;69:154–75.
- Shiozawa P, da Silva ME, Cordeiro Q, Fregni F, Brunoni AR. Transcranial direct current stimulation (tDCS) for catatonic schizophrenia: a case study. *Schizophr Res* 2013;146:374–5.
- Shiozawa P, Fregni F, Benseñor I, Lotufo PA, Berlim MT, Daskalakis JZ, et al. Transcranial direct current stimulation for major depression: an updated systematic review and meta-analysis. *Int J Neuropsychopharmacol* 2014;17:1443–52.
- Shirotta Y, Hewitt M, Paulus W. Neuroscientists do not use non-invasive brain stimulation on themselves for neural enhancement. *Brain Stimul* 2014;7:618–9.
- Smith RC, Boules S, Mattiuz S, Youssef M, Tobe RH, Sershen H, et al. Effects of transcranial direct current stimulation (tDCS) on cognition, symptoms, and smoking in schizophrenia: a randomized controlled study. *Schizophr Res* 2015;168:260–6.
- Sohn MK, Jee SJ, Kim YW. Effect of transcranial direct current stimulation on postural stability and lower extremity strength in hemiplegic stroke patients. *Ann Rehabil Med* 2013;37:759–65.
- Soler MD, Kumru H, Pelayo R, Vidal J, Tormos JM, Fregni F, et al. Effectiveness of transcranial direct current stimulation and visual illusion on neuropathic pain in spinal cord injury. *Brain* 2010;133:2565–77.
- Soltaninejad Z, Nejati V, Ekhtiari H. Effect of anodal and cathodal transcranial direct current stimulation on DLPFC on modulation of inhibitory control in ADHD. *J Atten Disord* 2016. <http://dx.doi.org/10.1177/1087054715618792>. in press.
- Sommer M, Wu T, Tergau F, Paulus W. Intra- and interindividual variability of motor responses to repetitive transcranial magnetic stimulation. *Clin Neurophysiol* 2002;113:265–9.
- Souto G, Borges IC, Goes BT, de Mendonça ME, Gonçalves RG, Garcia LB, et al. Effects of tDCS induced motor cortex modulation on pain in HTLV-1. A blind randomized clinical trial. *Clin J Pain* 2014;30:809–15.
- Stagg CJ, Best JG, Stephenson MC, O'Shea J, Wylezinska M, Kincses ZT, et al. Polarity-sensitive modulation of cortical neurotransmitters by transcranial stimulation. *J Neurosci* 2009;29:5202–6.
- Stagg CJ, Bachtiar V, O'Shea J, Allman C, Bosnell RA, Kischka U, et al. Cortical activation changes underlying stimulation-induced behavioural gains in chronic stroke. *Brain* 2012;135:276–84.
- Steenbergen L, Sellaro R, Hommel B, Lindenberger U, Kühn S, Colzato LS. "Unfocus" on focus: commercial tDCS headset impairs working memory. *Exp Brain Res* 2016;234:637–43.
- Strube W, Bunse T, Malchow B, Hasan A. Efficacy and interindividual variability in motor-cortex plasticity following anodal tDCS and paired-associative stimulation. *Neural Plast* 2015;2015:530423.
- Suemoto CK, Apolinario D, Nakamura-Palacios EM, Lopes L, Leite RE, Sales MC, et al. Effects of a non-focal plasticity protocol on apathy in moderate Alzheimer's disease: a randomized, double-blind, sham-controlled trial. *Brain Stimul* 2014;7:308–13.
- Swanson KD, Lok E, Wong ET. An overview of alternating electric fields therapy (NovoTTF therapy) for the treatment of malignant glioma. *Curr Neurol Neurosci Rep* 2016;16:8.
- Talelli P, Greenwood RJ, Rothwell JC. Arm function after stroke: neurophysiological correlates and recovery mechanisms assessed by transcranial magnetic stimulation. *Clin Neurophysiol* 2006;117:1641–59.
- Tecchio F, Cancelli A, Cottone C, Zito G, Pasqualetti P, Ghazaryan A, et al. Multiple sclerosis fatigue relief by bilateral somatosensory cortex neuromodulation. *J Neurol* 2014;261:1552–8.
- Tecchio F, Cancelli A, Cottone C, Ferrucci R, Vergari M, Zito G, et al. Brain plasticity effects of neuromodulation against multiple sclerosis fatigue. *Front Neurol* 2015;6:141.
- Tedesco Triccas L, Burridge JH, Hughes AM, Pickering RM, Desikan M, Rothwell JC, et al. Multiple sessions of transcranial direct current stimulation and upper extremity rehabilitation in stroke: a review and meta-analysis. *Clin Neurophysiol* 2016;127:946–55.
- Teismann H, Wollbrink A, Okamoto H, Schlaug G, Rudack C, Pantev C. Combining transcranial direct current stimulation and tailor-made notched music training to decrease tinnitus-related distress – a pilot study. *PLoS One* 2014;9:e89904.
- Tekturk P, Erdogan ET, Kurt A, Kocagoncu E, Kucuk Z, Kinay D, et al. Transcranial direct current stimulation improves seizure control in patients with Rasmussen encephalitis. *Epileptic Disord* 2016a;18:58–66.
- Tekturk P, Erdogan ET, Kurt A, Vanli-Yavuz EN, Ekizoglu E, Kocagoncu E, et al. The effect of transcranial direct current stimulation on seizure frequency of patients with mesial temporal lobe epilepsy with hippocampal sclerosis. *Clin Neurol Neurosurg* 2016b;149:27–32.
- Terney D, Chaieb L, Moliadze V, Antal A, Paulus W. Increasing human brain excitability by transcranial high-frequency random noise stimulation. *J Neurosci* 2008;28:14147–55.
- Thibaut A, Bruno MA, Ledoux D, Demertzi A, Laureys S. TDCS in patients with disorders of consciousness: Sham-controlled randomized double-blind study. *Neurology* 2014;82:1112–8.
- Toschi F, Lugli F, Biscarini F, Zerbetto F. Effects of electric field stress on a beta-amyloid peptide. *J Phys Chem B* 2009;113:369–76.
- Traversa R, Cicinelli P, Pasqualetti P, Filippi M, Rossini PM. Follow-up of interhemispheric differences of motor evoked potentials from the 'affected' and 'unaffected' hemispheres in human stroke. *Brain Res* 1998;803:1–8.

- Triccas LT, Burridge JH, Hughes A, Verheyden G, Desikan M, Rothwell J. A double-blinded randomised controlled trial exploring the effect of anodal transcranial direct current stimulation and uni-lateral robot therapy for the impaired upper limb in sub-acute and chronic stroke. *NeuroRehabilitation* 2015;37:181–91.
- Truini A, Vergari M, Biasiotta A, La Cesa S, Gabriele M, Di Stefano G, et al. Transcutaneous spinal direct current stimulation inhibits nociceptive spinal pathway conduction and increases pain tolerance in humans. *Eur J Pain* 2011;15:1023–7.
- Tsapkini K, Frangakis C, Gomez Y, Davis C, Hillis AE. Augmentation of spelling therapy with transcranial direct current stimulation in primary progressive aphasia: preliminary results and challenges. *Aphasiology* 2014;28:1112–30.
- Turrigiano GG, Nelson SB. Homeostatic plasticity in the developing nervous system. *Nat Rev Neurosci* 2004;5:97–107.
- Valentino F, Cosentino G, Brighina F, Pozzi NG, Sandrini G, Fierro B, et al. Transcranial direct current stimulation for treatment of freezing of gait: a cross-over study. *Mov Disord* 2014;29:1064–9.
- Valiengo L, Bensenor IM, Goulart AC, de Oliveira JF, Zanao TA, Boggio PS, et al. The sertraline versus electrical current therapy for treating depression clinical study (SELECT-TDCS): results of the crossover and follow-up phases. *Depress Anxiety* 2013;30:646–53.
- Valiengo L, Casati R, Bolognini N, Lotufo PA, Benseñor IM, Goulart AC, et al. Transcranial direct current stimulation for the treatment of post-stroke depression in aphasic patients: a case series. *Neurocase* 2016;22:225–8.
- Valle A, Roizenblatt S, Botte S, Zagli S, Riberto M, Tufik S, et al. Efficacy of anodal transcranial direct current stimulation (tDCS) for the treatment of fibromyalgia: results of a randomized, sham-controlled longitudinal clinical trial. *J Pain Manage* 2009;2:353–61.
- van Asseldonk EH, Boonstra TA. Transcranial direct current stimulation of the leg motor cortex enhances coordinated motor output during walking with a large inter-individual variability. *Brain Stimul* 2016;9:182–90.
- van Kuijk AA, Pasman JW, Hendricks HT, Zwarts MJ, Geurts AC. Predicting hand motor recovery in severe stroke: the role of motor evoked potentials in relation to early clinical assessment. *Neurorehabil Neural Repair* 2009;23:45–51.
- Vandermeeren Y, Lefebvre S, Desfontaines P, Laloux P. Could dual-hemisphere transcranial direct current stimulation (tDCS) reduce spasticity after stroke? *Acta Neurol Belg* 2013;113:87–9.
- Vanneste S, De Ridder D. Bifrontal transcranial direct current stimulation modulates tinnitus intensity and tinnitus-distress-related brain activity. *Eur J Neurosci* 2011;34:605–14.
- Vanneste S, De Ridder D. Deafferentation-based pathophysiological differences in phantom sound: tinnitus with and without hearing loss. *Neuroimage* 2015;129:80–94.
- Vanneste S, Plazier M, Ost J, van der Loo E, Van de Heyning P, De Ridder D. Bilateral dorsolateral prefrontal cortex modulation for tinnitus by transcranial direct current stimulation: a preliminary clinical study. *Exp Brain Res* 2010;202:779–85.
- Vanneste S, Focquaert F, Van de Heyning P, De Ridder D. Different resting state brain activity and functional connectivity in patients who respond and not respond to bifrontal tDCS for tinnitus suppression. *Exp Brain Res* 2011;210:217–27.
- Vanneste S, Fregni F, De Ridder D. Head-to-head comparison of transcranial random noise stimulation, transcranial AC stimulation, and transcranial DC stimulation for tinnitus. *Front Psychiatry* 2013a;4:158.
- Vanneste S, Walsh V, Van De Heyning P, De Ridder D. Comparing immediate transient tinnitus suppression using tACS and tDCS: a placebo-controlled study. *Exp Brain Res* 2013b;226:25–31.
- Verheyden G, Purdey J, Burnett M, Cole J, Ashburn A. Immediate effect of transcranial direct current stimulation on postural stability and functional mobility in Parkinson's disease. *Mov Disord* 2013;28:2040–1.
- Viana RT, Laurentino GE, Souza RJ, Fonseca JB, Silva Filho EM, Dias SN, et al. Effects of the addition of transcranial direct current stimulation to virtual reality therapy after stroke: a pilot randomized controlled trial. *NeuroRehabilitation* 2014;34:437–46.
- Villamar MF, Wivatvongvana P, Patumanond J, Bikson M, Truong DQ, Datta A, et al. Focal modulation of the primary motor cortex in fibromyalgia using 4x1-ring high-definition transcranial direct current stimulation (HD-tDCS): immediate and delayed analgesic effects of cathodal and anodal stimulation. *J Pain* 2013;14:371–83.
- Vines BW, Norton AC, Schlaug G. Non-invasive brain stimulation enhances the effects of melodic intonation therapy. *Front Psychol* 2011;2:230.
- Volpato C, Cavinato M, Piccione F, Garzon M, Meneghello F, Birbaumer N. Transcranial direct current stimulation (tDCS) of Broca's area in chronic aphasia: a controlled outcome study. *Behav Brain Res* 2013;15:211–6.
- Volz MS, Farmer A, Siegmund B. Reduction of chronic abdominal pain in patients with inflammatory bowel disease through transcranial direct current stimulation: a randomized controlled trial. *Pain* 2016;157:429–37.
- Von Papen M, Fisse M, Sarfeld AS, Fink GR, Nowak DA. The effects of 1 Hz rTMS preconditioned by tDCS on gait kinematics in Parkinson's disease. *J Neural Transm* 2014;121:743–54.
- Wang J, Wu D, Chen Y, Yuan Y, Zhang M. Effects of transcranial direct current stimulation on language improvement and cortical activation in nonfluent variant primary progressive aphasia. *Neurosci Lett* 2013;549:29–33.
- Wang J, Wei Y, Wen J, Li X. Skin burn after single session of transcranial direct current stimulation (tDCS). *Brain Stimul* 2015;8:165–6.
- Ward NS, Brown MM, Thompson AJ, Frackowiak RS. Neural correlates of motor recovery after stroke: a longitudinal fMRI study. *Brain* 2003;126:2476–96.
- Wexler A. The practices of do-it-yourself brain stimulation: implications for ethical considerations and regulatory proposals. *J Med Ethics* 2016;42:211–5.
- Wickmann F, Stepiani C, Czesnik D, Klinker F, Timäus C, Chaieb L, et al. Prophylactic treatment in menstrual migraine: a proof-of-concept study. *J Neurol Sci* 2015;354:103–9.
- Wiethoff S, Hamada M, Rothwell JC. Variability in response to transcranial direct current stimulation of the motor cortex. *Brain Stimul* 2014;7:468–75.
- Wilson SJ, Sayette MA, Fiez JA. Prefrontal responses to drug cues: a neurocognitive analysis. *Nat Neurosci* 2004;7:211–4.
- Winkler T, Hering P, Straube A. Spinal DC stimulation in humans modulates post-activation depression of the H-reflex depending on current polarity. *Clin Neurophysiol* 2010;121:957–61.
- Wolkenstein L, Plewnia C. Amelioration of cognitive control in depression by transcranial direct current stimulation. *Biol Psychiatry* 2013;73:646–51.
- Wood M, Willits RK. Short-duration, DC electrical stimulation increases chick embryo DRG neurite outgrowth. *Bioelectromagnetics* 2006;27:328–31.
- Woods AJ, Antal A, Bikson M, Boggio PS, Brunoni AR, Celnik P, et al. A technical guide to tDCS, and related non-invasive brain stimulation tools. *Clin Neurophysiol* 2016;127:1031–48.
- Wrigley PJ, Gustin SM, McIndoe LN, Chakiath RJ, Henderson LA, Siddall PJ. Longstanding neuropathic pain after spinal cord injury is refractory to transcranial direct current stimulation: a randomized controlled trial. *Pain* 2013;154:2178–84.
- Wu T, Hallett M. The cerebellum in Parkinson's disease. *Brain* 2013;136:696–709.
- Wu D, Qian L, Zorowitz RD, Zhang L, Qu Y, Yuan Y. Effects on decreasing upper-limb poststroke muscle tone using transcranial direct current stimulation: a randomized sham-controlled study. *Arch Phys Med Rehabil* 2013;94:1–8.
- Wu D, Wang J, Yuan Y. Effects of transcranial direct current stimulation on naming and cortical excitability in stroke patients with aphasia. *Neurosci Lett* 2015;589:115–20.
- Xu J, Fregni F, Brody AL, Rahman AS. Transcranial direct current stimulation reduces negative affect but not cigarette craving in overnight abstinent smokers. *Front Psychiatry* 2013;4:112.
- Yang EJ, Baek SR, Shin J, Lim JY, Jang HJ, Kim YK, et al. Effects of transcranial direct current stimulation (tDCS) on post-stroke dysphagia. *Restor Neurol Neurosci* 2012;30:303–11.
- Yang SN, Pyun SB, Kim HJ, Ahn HS, Rhyu BJ. Effectiveness of non-invasive brain stimulation in dysphagia subsequent to stroke: a systemic review and meta-analysis. *Dysphagia* 2015;30:383–91.
- Yeganeh-Doost P, Gruber O, Falkai P, Schmitt A. The role of the cerebellum in schizophrenia: from cognition to molecular pathways. *Clinics (Sao Paulo)* 2011;66(Suppl 1):71–7.
- Yoon EJ, Kim YK, Kim HR, Kim SE, Lee Y, Shin HL. Transcranial direct current stimulation to lessen neuropathic pain after spinal cord injury: a mechanistic PET study. *Neurorehabil Neural Repair* 2014;28:250–9.
- You DS, Kim DY, Chun MH, Jung SE, Park SJ. Cathodal transcranial direct current stimulation of the right Wernicke's area improves comprehension in subacute stroke patients. *Brain Lang* 2011;119:1–15.
- Zheng X, Schlaug G. Structural white matter changes in descending motor tracts correlate with improvements in motor impairment after undergoing a treatment course of tDCS and physical therapy. *Front Hum Neurosci* 2015;9:229.
- Zimmerman M, Heise KF, Hoppe J, Cohen LG, Gerloff C, Hummel FC. Modulation of training by single-session transcranial direct current stimulation to the intact motor cortex enhances motor skill acquisition of the paretic hand. *Stroke* 2012;43:2185–91.
- Zuchowski ML, Timmann D, Gerwig M. Acquisition of conditioned eyeblink responses is modulated by cerebellar tDCS. *Brain Stimul* 2014;7:525–31.